

Surgical treatment of acute burns

KEY WORDS

- ▶ Burn
- ▶ Excision
- ▶ Skin grafting
- ▶ Surgery

One of the most common problems facing the medical professional treating acute burn injuries is whether it should be treated conservatively or surgically. The aim of this article is to provide the reader with a framework for comprehensive assessment of the burn and to introduce the steps and considerations involved in surgically treating these injuries.

In the UK, major traumatic injury is the leading cause of death in individuals aged <40 years with burn injury, accounting for 1 in every 20 serious traumatic injuries sustained (National Audit Office, 2010; Kalson et al, 2012). In the older age group (>65 years), burns are the third most frequent cause of accidental mortality, with only falls and road traffic accidents being more common (Soreide and Grande, 2001). Continued improvements in all aspects of the care of burn injury victims have resulted in marked reductions in mortality rates in developed countries; from 54–100% at the beginning of the twentieth century to around 4–6% currently (Sneve, 1905; Dunbar, 1934; Miller et al, 2008; Belgian Outcome Burn Injury Study Group, 2009; Osler et al, 2010; Steinvall et al, 2011). Significant advances in the surgical treatment of burns have played a major part in reducing the rates of sepsis, excessive scarring and mortality, and length of hospital stay by enabling the early closure of wounds and reducing complications. One of the major decisions facing medical staff treating burn patients is the decision on the choice of treatment (i.e. conservative versus surgical treatment).

The aim of this article is to provide an insight into the accurate assessment of burns, which will help to identify burns that require surgical treatment and outline surgical planning and choices.

BURN WOUND ASSESSMENT

Major burn injuries are potentially life threatening and initial assessment of these injuries should be treated as such. Immediate assessment should be along principles of airway assessment for inhalation injury, with cervical spine stabilisation, breathing assessment with

ventilation support, circulatory assessment treatment of shock, assessment of neurological disability, and exposure with environmental control. The severity of burn injury is documented in terms of extent (i.e. percentage of total body surface area [TBSA] involved) and depth. Inhalation injury should be suspected in all patients who present with history of entrapment or delayed evacuation from a confined burning environment, especially if there is concomitant history of loss of consciousness. High flow oxygen therapy should be initiated immediately in all patients with suspected inhalation injury and specialist assessment should be sought from an anaesthetist.

Burn shock is the major cause of early mortality in burns and unlike shock resulting from other forms of trauma, is the consequence of fluid leak from the intravascular compartment. Adults with burns of 15% TBSA, and children with 10% TBSA, should be resuscitated using the Parkland formula, i.e. 3 mL–4 mL of Hartman's solution/kg body weight/%TBSA, with half the total fluid given over the first 8 hours following the injury and the remaining given over the next 16 hours. Children (<16 years) should also be given maintenance fluid in the form of 0.45% normal saline/5% dextrose, as their renal tubular function is not fully developed and glycogen stores are easily depleted. These patients should also have a urinary catheter introduced to allow accurate, hourly assessment of urine output, as this remains the most reliable clinical indicator of adequate tissue perfusion. In adults, target urine output should be 35 mL–50 mL/hour, and 1 mL/kg/hour in children (Fabia, 2016).

The most important factor that determines whether a burn is treated conservatively or by

Table 1. Physical characteristics of different types of burns

	Blisters	Colour	Sensation	Capillary refill	Treatment
Superficial dermal	Yes	Pink	Painful	Present (brisk)	Conservative
Mid dermal	Yes	Red	Painful	Present (slow)	Conservative
Deep dermal	No	Cherry red	Dull	Absent	Surgical
Full thickness	No	White, leathery	Absent	Absent	Surgical

surgical intervention is the depth of involvement, which in turn determines the healing potential of the injury. Knowledge of skin structure is vital for accurate assessment of burns. The skin is the largest organ in the body and is divided into two distinct layers: the outer epidermis and the inner dermis. The epidermis is composed of a layer of cells that perform protective and immune functions, whereas the dermis is composed of fibres and cells that are spread out in a cellular ground substance. The dermis contains plexuses of blood vessels and nerves, which provide nourishment and sensibility to both the dermis and epidermis. In addition, the dermis also contains hair follicles, sweat glands and sebaceous glands, which extend from the dermis to the skin surface. The lining of these dermal appendages acts as a reservoir of epithelial cells that can mobilise to restore epithelial continuity of superficial wounds.

A thorough clinical assessment is essential to accurately classify burns as those involving either partial or full skin thickness based on the physical characteristics of the wound. These characteristics include presence of blistering, wound bed colour, sensibility and capillary blush on release of digital pressure (*Table 1*). The presence of a break in epidermal continuity is an essential feature of burns. Redness in the absence of epidermal breakdown, such as that seen in superficial sunburn, although painful, does not require intervention apart from symptomatic treatment. Partial thickness burns are associated with epidermal blistering and are further divided into superficial (involving the superficial and mid dermis) and deep (involving deeper part of the dermis) partial thickness burns. In superficial dermal and mid dermal burns the cutaneous nerves, dermal vascular plexuses and appendages located in the deep dermis are intact, resulting

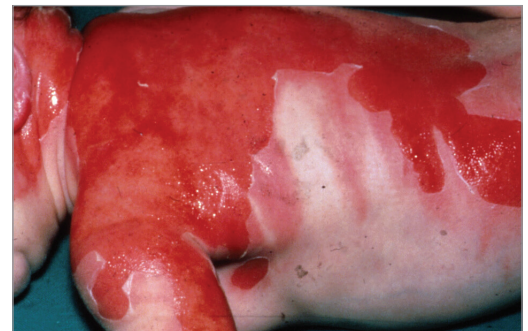

Figure 1. Superficial partial thickness scald

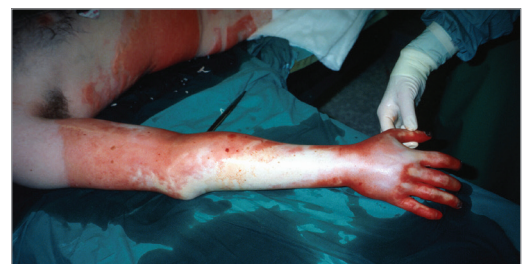

Figure 2. Circumferential deep dermal burn over arm, forearm and hand. Note the patches of full-thickness (white) burn over the extensor forearm and hand

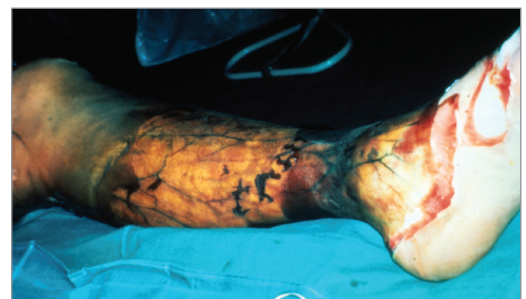

Figure 3. Full-thickness flame burn circumferentially involving the leg

in wounds that are pink or red in colour, have a wet exuding surface, are painful and have a capillary refill (*Figure 1*). As the dermal appendages are intact in these burns, there is no need for surgical intervention and they can be

ACKNOWLEDGMENT
 This article is an update of a previously published article (*Wounds UK*9(1): 54–9)

treated conservatively with appropriate dressings (e.g. FLAMAZINE™ Cream [silver sulfadiazine; Smith & Nephew], Betadine® Solution [Purdue Pharma], etc) and are expected to heal in 10–14 days. Superficial burns can also be treated with temporary skin substitutes such as Suprathel® (single application dressing comprising poly DL lactic acid; PolyMedics Innovations) and Biobrane® (bi-layer dressing comprising inner nylon mesh impregnated with porcine collagen layer and outer porous silicone layer; Smith & Nephew). Skin substitutes are tissue engineered products that are designed to replace the form and function of lost skin. These can be temporary (providing temporary cover that allows healing of the wound bed, e.g. Biobrane® and Suprathel®) which are useful in managing superficial partial thickness burns or permanent (that provide a scaffold for healing tissue and are permanently incorporated, e.g. INTEGRA® [bi-layer dermal regeneration template comprising inner collagen scaffold and external silicone layer to control moisture loss; LifeSciences] and MatriDerm® [single layer dermal substitute comprising bovine tendon collagen and nuchal elastin; MedSkin Solutions], which are used to resurface deep dermal or full thickness burns. Temporary skin substitutes (Biobrane® and Suprathel®) have been shown to reduce healing time, pain associated with dressing changes and reduced inpatient length of stay when used to treat superficial partial thickness burns especially in children (Schwarze et al, 2008; Leshner et al, 2011).

In deep dermal burns, the vascular structure of the dermis and the dermal appendages are destroyed along with the cutaneous nerves and dermal appendages (Figure 2). As a consequence, deep dermal burns have a deep cherry-red colour, a dry surface, dull sensation and absent capillary refilling, which will heal with considerable scarring unless treated by surgical intervention. Full-thickness burns involve the entire thickness of skin and present as a dry, leathery eschar, which is insensate, and these burns, unless treated surgically, will result in increased risk of scarring, sepsis and mortality (Figure 3).

Specialised burn services use Laser Doppler Imaging (LDI) as an adjunct to clinical evaluation for increased accuracy in identifying burns that

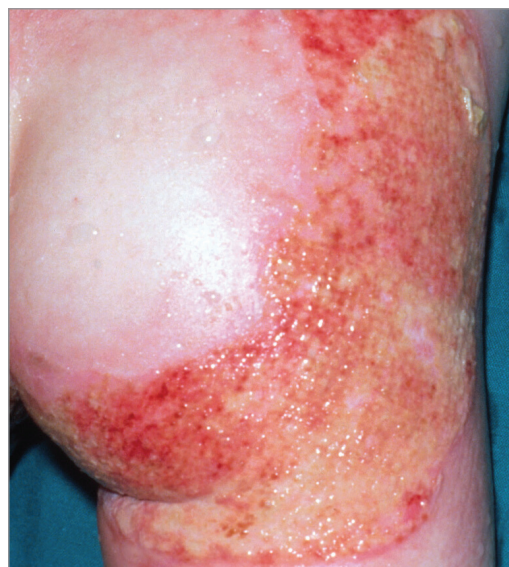

Figure 4. FLAMAZINE® coating the surface of a superficial partial-thickness scald, giving it the appearance of a deeper injury

will require surgical treatment. LDI identifies poor blood flow in dermal vascular plexuses and has demonstrated a diagnostic accuracy of 95–100% in several prospective studies (Jeng et al, 2003; Hoeksema et al, 2009; Monstrey et al, 2011). The timing of LDI assessment is important as scanning between 48 hours and 5 days post-burn has been shown to result in >95% accuracy (Hoeksema et al, 2011).

In addition to the depth of a burn, factors such as size of the burn, anatomical site of injury, patient age, general health and associated comorbid conditions also play a role in selecting patients for surgical treatment. In line with National Burn Care Referral Guidelines (2012), all patients sustaining deep dermal and full-thickness burns, irrespective of age, extent of injury and comorbidities, should be referred to a specialist burn service.

PITFALLS IN BURN WOUND ASSESSMENT

Certain primary dressings applied to acute burns can mask the appearance of the wound, thus making it difficult to assess the depth of injury. This is particularly the case with FLAMAZINE®, a commonly used topical burn dressing that induces a neutrophilic exudate that coats the burn surface (Figure 4). This dressing type should only be used

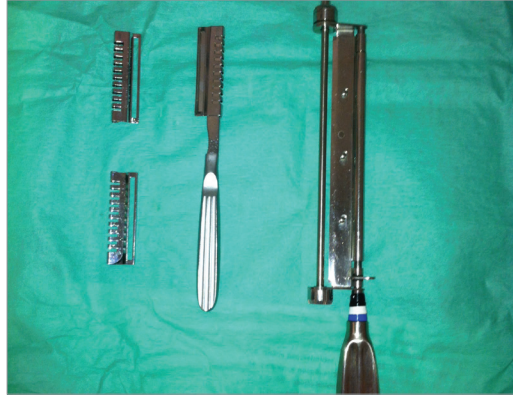


Figure 5. Watson blade (right) and Goulian blade with guards (left)

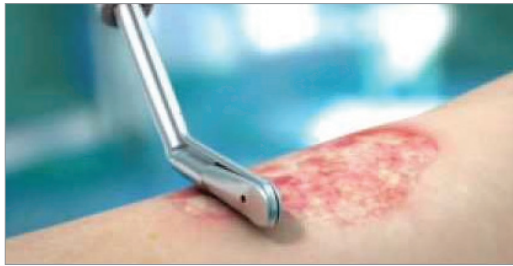

Figure 6. Versajet® II (Smith & Nephew) being used to debride a burn

after an accurate assessment of the depth is made by an experienced clinician, as well as a decision to pursue conservative treatment.

Burn wounds are dynamic especially in the initial stages, and a burn that appears superficial on initial assessment may progress to a deeper injury over the course of a few days. This may be the result of inadequate initial treatment or superadded infection. In these cases, well-documented serial clinical assessment allows the early recognition of burn progression and the timely initiation of appropriate treatment.

BURN WOUND MANAGEMENT

Once a decision is made to treat a burn injury surgically, the next decisions facing burn service clinicians include when to perform surgery, which technique to employ and how to close the resulting wounds. The principal objectives for surgical treatment are to excise all nonviable burnt tissue while preserving as much viable tissue as possible, and to close the resulting wound early to reduce complications while minimising the

effects of surgery on the patient. Early excision of deep dermal and full-thickness burns (within 7 days post-injury) has been shown to reduce the incidence of post-operative complications, morbidity and length of hospital stay, and improved functional results (Deitch, 1985; Pietsch et al, 1985; Ong et al, 2006).

Excision of the burn is performed in the operating theatre under aseptic conditions with the ambient temperature tightly regulated to minimise the risk of hypothermia, especially in more extensive burns. The surgical techniques available for excision of the burn include tangential excision and fascial excision, and selection is dependent on the depth of injury, risk of bleeding and general condition of the patient. Tangential excision is used to excise deep dermal and full-thickness burns and allows removal of the burn in wafer-thin layers until viable tissue (dermis or subcutaneous fat) is encountered, thus minimising the excision of healthy tissue. Punctate bleeding and healthy colour as well as texture indicate viability of tissue deep to the burn. This technique has the advantages

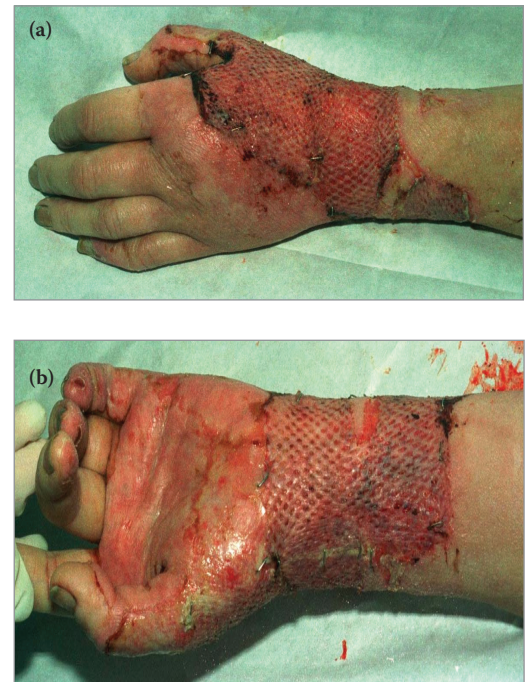

Figure 7. (a) Meshed skin graft to the radial border of the hand following excision of a deep dermal burn (b) Meshed skin graft to the flexor aspect of wrist following excision of a deep dermal burn

REFERENCES

- Belgian Outcome Burn Injury Study Group (2009) Development and validation of a model for prediction of mortality in patients with acute burn injury. *Br J Surg* 96(1):111–7
- Deitch EA (1985) A policy of early excision and grafting in elderly burn patients shortens the hospital stay and improves survival. *Burns Incl Therm Inj* 12(2):109–14
- Dunbar J (1934) Review of the burn cases treated in the Glasgow Royal Infirmary during the past hundred years (1833–1933) with some observations on present day treatment. *Glasgow Med J* 122:239–55
- Fabia R (2016) Surgical Treatment of Burns in Children Treatment & Management. Available at: <http://bit.ly/1cVqrPA> (accessed 18.01.2018)
- Hoeksema H, Van de Sijpe K, Tondt T et al (2009) Accuracy of early burn depth assessment by laser Doppler imaging on different days post burn. *Burns* 35(1):36–45
- Jeng JC, Bridgeman A, Shivan L et al (2003) Laser Doppler imaging determines need for excision and grafting in advance of clinical judgment: a prospective blinded trial. *Burns* 29(7):665–70
- Kalson NS, Jenks T, Woodford M et al (2012) Burns represent a significant proportion of the total serious trauma workload in England and Wales. *Burns* 38(3):330–9
- Leshner AP, Curry RH, Evans J et al (2011) Effectiveness of Biobrane for the treatment of partial-thickness burns in children. *J Pediatr Surg* 46(9):1759–63
- Miller SF, Bessey P, Lentz CW (2008) National burn repository 2007 report: a synopsis of the 2007 call for data. *J Burn Care Res* 29(6):862–70
- Monstrey SM, Hoeksema H, Baker RD et al (2011) Burn wound healing time assessed by laser Doppler imaging. Part 2: validation of a dedicated colour code for image interpretation. *Burns* 37(2):249–56
- National Audit Office (2010) Major Trauma Care in England. Available at: <http://bit.ly/19J27vt> (accessed 18.01.2018)
- National Network for Burn Care (2012) National Burn Care Referral Guidance. National Network for Burn Care: UK. Available at: http://www.britishburnassociation.org/downloads/National_Burn_Care_Referral_Guidance_-_5.2.12.pdf (accessed 18.01.2018)
- Ong YS, Samuel M, Song C (2006) Meta-analysis of early excision of burns. *Burns* 32(2):145–50
- of being easy to perform while minimising the contour and cosmetic defects that will result from excision of tissue. TE can be performed using specially designed surgical instruments such as the eponymous Goulian and Watson blades (*Figure 5*) or using hydrosurgery (Versajet® II; Smith & Nephew; *Figure 6*) that employs a self-contained high-pressure fluid jet system to remove dead tissue. The latter is especially useful in regions of the body, such as face and hands, where conserving viable tissue is essential to reduce cosmetic and functional consequences of surgery.
- Fascial excision is used to remove extensive full-thickness burns by removing all skin and subcutaneous tissue to the level of the fascia. This technique is useful where the risk of bleeding from extensive wounds would be unacceptable when subjected to conventional tangential excision. However, the disadvantage of this technique is that it results in significant cosmetic and contour deformities.
- Once the burn wound has been excised, the technique most commonly used for covering the wound is split-thickness skin grafting (SSG). This involves removing a thin shave of skin comprising the epidermis and a part of the dermis, only leaving behind the deeper part of the dermis along with the dermal vasculature and appendages. The resulting wound after the SSG is harvested does not require closure as it will epithelialise spontaneously after 10–14 days. An advantage of this technique is that there is usually an abundance of donor sites from which SSG can be harvested and as the donor site heals the same site can be used to harvest further grafts. The most commonly used donor sites include the anterolateral thigh and upper arm as these sites are easy to access and manage with dressings, heal well and the resulting wounds can easily be concealed by clothing.
- The process of “meshing” is often used to increase the surface area over which the SSG can be applied (*Figure 7a and b*). This not only has the advantage of reducing the size of donor site required to cover a larger area of burn wound, but also the interstices of the meshed graft prevent the accumulation of blood and tissue fluid deep to the graft, which can prevent SSG from adhering to the wound bed. In an appropriately prepared wound, the process of the SSG adhering to the wound bed begins as soon as the graft is applied to it. This is due to the bleeding surface forming fibrin bonds with the undersurface of the graft. Within the first 72 hours, the graft relies on tissue fluid from the wound for survival; after this time, blood vessels from the wound begin to grow into the graft re-establishing a reliable blood supply, which can take 3–7 days. Until a reliable blood supply to the graft is established, the connections between the graft and wound bed are prone to shearing, resulting in graft loss. This can be minimised by the use of bulky dressings and splints, especially when limbs are grafted. The graft can be exposed after 7–10 days and will require regular moisturising, as the grafted skin has less sweat and sebaceous glands than non-grafted skin. The graft matures by the process of remodeling, which can take up to 18 months, giving the graft its final appearance. The common late problems encountered with SSG include hypo- or hyper-pigmentation, contour deformity and cosmetic concerns, but the procedure is well tolerated by patients and gives consistently predictable results, thus warranting its widespread use to resurface burn wounds.
- In addition to SSGs, full-thickness skin grafts (FTSGs) can also be employed in the treatment of burns especially those involving aesthetically and functionally sensitive areas (face, hands and joints). In contrast with SSG, an FTSG is harvested incorporating the entire thickness of the epidermis and dermis and the resulting defect requires direct closure. FTSG have the advantage of reduced contraction and better aesthetic match to burnt tissue.
- However, their use, especially in extensive burns, is limited by higher metabolic demand and shortage of donor sites. Infrequently debridement of deep dermal and full-thickness burns results in the exposure of tendons, joints, vessels and nerves, which require durable soft tissue coverage. In these cases vascularised tissue is recruited either from the vicinity of the burn (local flap) or from distant sites (pedicled or free-tissue transfer).
- In extensive burns, there is often a shortage of donor sites for SSG. In these situations,

Osler T, Glance LG, Hosmer DW (2010) Simplified estimates of the probability of death after burn injuries: extending and updating the baux score. *J Trauma* 68(3): 690–7

Pietsch JB, Netscher DT, Nagaraj HS, Groff DB (1985) Early excision of major burns in children: effect on morbidity and mortality. *J Pediatr Surg* 20(6):754–7

Schwarze H, Kuntscher M, Uhlig C et al (2008) Suprathel, a new skin substitute in the management of partial thickness burn wounds: results of a clinical study. *Ann Plast Surg* 60(2):181–5

Sneve H (1905) The treatment of burns and skin grafting. *JAMA* 45(1):1–8

Soreide E, Grande CM (2001) *Prehospital Trauma Care*. Marcel Dekker, New York, NY

Steinvall I, Fredrikson M, Bak Z, Sjöberg F (2011) Mortality after thermal injury: no sex-related difference. *J Trauma* 70(4):959–64

appropriately debrided burn surfaces can be covered with cadaveric skin (allograft). This serves as a temporizing measure not only preventing the desiccation and infection of wounds but also promoting vascular ingrowth optimising future SSG take. A sandwich technique, commonly referred to as Alexander technique, can also be employed in extensive burns which involves a widely meshed SSG covered with cadaveric allograft. Both the SSG and allograft adhere to the wound bed and as the SSG epithelialises to fill in the interstices of the mesh, the allograft separates. Dermal substitutes, such as INTEGRA® (LifeSciences) and MatriDerm® (MedSkin Solutions), are synthetic scaffolds that are increasingly used in modern acute burn surgery and allow ingrowth of native tissue along a scaffold, which is resorbed gradually. The dermal substitute is covered with

SSG, which is either performed at the same time or is delayed. These dermal substitutes have the advantage of improved long-term pliability, elasticity, and appearance of scars.

CONCLUSION

A comprehensive clinical examination is essential for early identification of burn injuries that will benefit from surgical treatment. In superficial partial-thickness burns, the dermal appendages and blood flow in the dermal vascular plexuses are preserved, hence these are managed conservatively. In deep dermal and full-thickness burns, the dermal vascular flow and appendages are disrupted and these require surgical treatment. Early surgical treatment in the form of excision and immediate SSG minimises complications and optimises functional results.

WUK

Treat infected leg ulcers, pressure ulcers and diabetic foot ulcers with Anabact 0.75% w/w Gel Metronidazole

✓ **Clinically proven** to rapidly reduce pain and infection as well as discharge and smell

(Finlay. IG. et al. J. Pain Symptom Management. 1996; 11(3); 158-162)

www.cambridge-healthcare.co.uk

For further information contact: sandi@chsl.co.uk

Information about this product, including adverse reactions, precautions, contra-indications and method of use can be found at www.cambridge-healthcare.co.uk.

Prescribers are recommended to consult the summary of product characteristics before prescribing.

Adverse events should be reported. Reporting forms and information can be found at www.mhra.gov.uk/yellowcard.

Adverse events should also be reported to Cambridge Healthcare Supplies Ltd. Tel: 01953 607856 | Email: customerservices@cambridge-healthcare.co.uk



Legal category: POM