

# A 22-patient clinical evaluation of Kliniderm debride and Kliniderm debride pocket

**KEY WORDS**

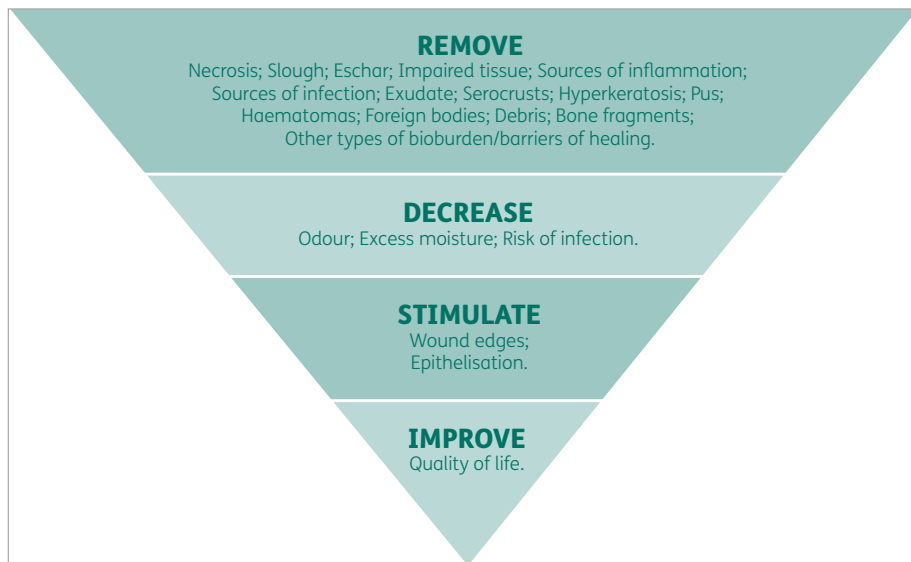
- ▶▶ Debridement
- ▶▶ Kliniderm debride
- ▶▶ Kliniderm debride pocket
- ▶▶ Product evaluation

Wound debridement is the process whereby foreign material, and dead or damaged tissue and debris, are removed from a wound (Vowden and Vowden, 1999; O'Brien, 2002; O'Brien, 2003). There are many forms of debridement: Kliniderm debride and Kliniderm debride pocket (H&R Healthcare) were used as part of an evaluation, which involved mechanical debridement of complex wounds and periwound skin. In total, the evaluation included 23 wounds with a variety of aetiologies. The products showed effective wound debridement and the clinicians considered the products easy to use.

Wound bed preparation is the key element to ensuring optimum wound healing (Falanga, 2000; Schultz et al, 2003). Effective wound bed preparation involves holistic assessment of the patient and a structured approach to recording the wound assessment. The Skin Integrity Team use the TIMES acronym (tissue, infection/inflammation, moisture balance, edge, surrounding skin) to undertake and document wound assessment; this incorporates the key elements in wound healing and can identify any barriers that may delay the healing process, encompassing not only the wound but the wound edges and periwound skin (Wounds UK, 2016). Wolcott et al (2009) highlights that wound debridement has a key part to play in wound care, involving the removal of non-viable tissue, infected

tissue, biofilm, foreign material and/or debris from the wound bed. It is generally accepted that necrotic tissue must be removed as quickly and efficiently as possible to assist with wound assessment, reduce bioburden (Reid and Morison, 1994), remove biofilms and prevent infection (Ayello and Cuddigan, 2004). Devitalised tissue, non-viable tissue and debris can inhibit the stages of healing; therefore, effective wound debridement aids the wound to follow the wound healing continuum without delay, leading to a positive outcome on the patient's quality of life, (JWC, 2013) as shown (Figure 1). Devitalised tissue, non-viable tissue and debris can inhibit the stages of wound healing by:

- ▶▶ Creating a physical barrier for healing (Kubo et al, 2001)



**Figure 1.**  
Benefits of debridement in practice

LOUISE WALL  
Skin Integrity Specialist Sister,  
Doncaster and Bassetlaw  
Teaching Hospitals NHS  
Foundation Trust

KELLY MOORE  
Skin Integrity Lead Nurse,  
Doncaster and Bassetlaw  
Teaching Hospitals NHS  
Foundation Trust

- » Inhibiting the growth of granulation/epithelial tissue
- » Increasing the production of exudate
- » Making it more difficult to achieve wound bed closure
- » Preventing effectiveness of topical treatments
- » Obscuring signs of infection and/or mimicking signs of infection (O'Brien, 2002)
- » Increasing the risk for bacterial growth such as *Bacteroides* species and *Clostridium perfringens* (Leaper, 2002)
- » Altering tissue formation (Weir et al, 2007)
- » Obscuring the wound bed, preventing accurate wound assessment (Leaper, 2002; Weir et al, 2007).

Types of debridement include:

- » **Surgical:** performed in a theatre setting by a trained surgeon; this is considered to be very invasive
- » **Sharp:** can be performed at the patient's bedside, or in the clinic environment, with the use of scalpel, curette or scissors and is performed by a skilled practitioner
- » **Mechanical:** the most common form of wound debridement and can involve the use of irrigation used with high pressure fluid and/or a monofilament soft pad
- » **Enzymatic:** the use of chemical ingredients that are applied to devitalised tissue to soften
- » **Larval therapy:** sterile larvae applied to devitalised tissue, which produce enzymes to autolytically debride the tissue, used in healthcare settings
- » **Ultrasonic:** performed by a trained healthcare specialist; challenges to use include limited availability, high costs, and patients may require multiple treatments
- » **Autolytic:** commonly carried out through use of hydrogel or alginate to donate moisture to devitalised tissue; this is non-invasive but can be a slow process.

Wound cleansing and debridement have become part of the standard wound bed preparation at Doncaster and Bassetlaw Teaching Hospitals NHS Foundation Trust since 2016 and across Doncaster Wound Care Alliance since 2019. Mechanical debridement is performed on all complex wounds reviewed in the Complex Wound Clinic by the Skin

Integrity Team; we aim to remove the barriers to wound healing involving the wound bed, wound edges and periwound care (see Figure 2).

Mechanical debridement is the most common effective debridement, which can be performed safely by healthcare professionals, patients and carers, as minimal training is required. Prior to performing any form of debridement, it is important to obtain consent from the patient. Wilcox et al (2013) reports that the use of mechanical debridement as part of wound care can improve the rate at which a wound heals if used as part of a regular wound assessment.

The benefits of debridement include:

- » Aiding wound assessment and allowing accurate assessment of the extent of tissue destruction
- » Restarting the healing process by addressing the 'prolonged' or 'stalled' inflammatory response, reducing excess matrix metalloproteinase production and the likelihood of a septic response
- » Removing tissue acting as a physical barrier to healing
- » Reducing bioburden, including biofilm, and reducing the risk of infection, as devitalised tissue may serve as a source of nutrients for bacteria
- » Removing devitalised tissue that may mask or mimic signs of infection
- » Reducing odour
- » Reducing excess moisture
- » Enabling topical agents to be used effectively
- » Stimulating the wound edges and epithelialisation
- » Reducing potential pain associated with devitalised tissue
- » Improving quality of life (Wolcott et al, 2010; Gray et al, 2011; Strohal et al, 2013; Davies et al, 2015; Percival and Suleman, 2015; Anghel et al, 2016).

An evaluation was undertaken by the Skin Integrity Team in the complex wound clinic from 2021 to 2022, using Kliniderm debride and Kliniderm debride pocket to identify whether these products provided the same clinical outcomes as the current product used.

#### WHAT IS KLINIDERM DEBRIDE?

Kliniderm debride is a monofilament pad designed to provide rapid, effective mechanical debridement.

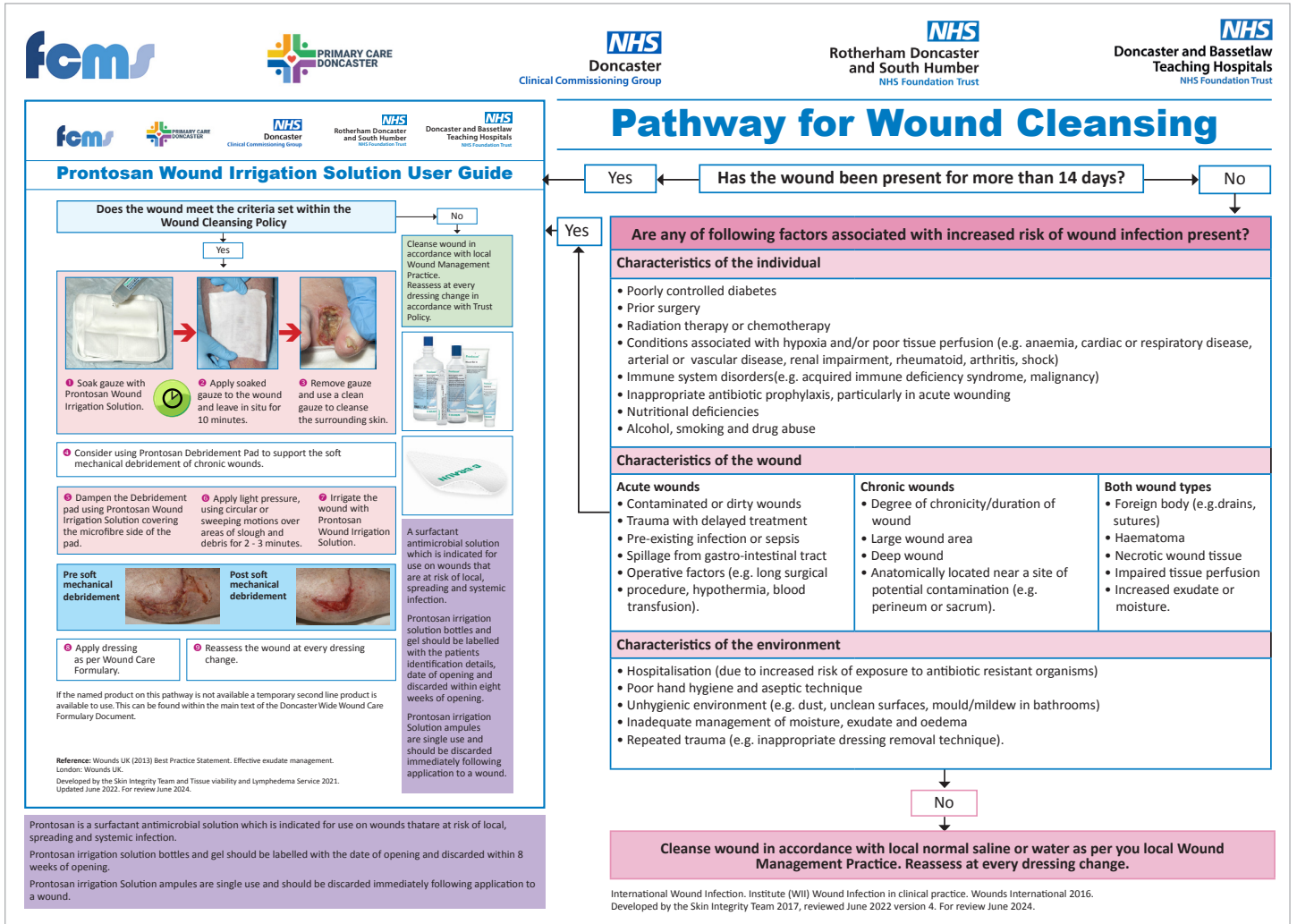


Figure 2. Doncaster and Bassetlaw Teaching Hospitals NHS Foundation Trust pathway for wound cleansing

It is constructed of single continuous polyester fibre filament; the polyester monofilament fibre yarn is used to create loops on the surface of the pad. Per square cm<sup>2</sup> of pad:

- ▶▶ Density of 9504 monofilaments
- ▶▶ Weight of 0.044 grams
- ▶▶ The loops are approximately 7mm high with a density of 33 loops.

The backing layer of the fabric is a polypropylene film, fixed by heat to make the inner layer of the product water-resistant.

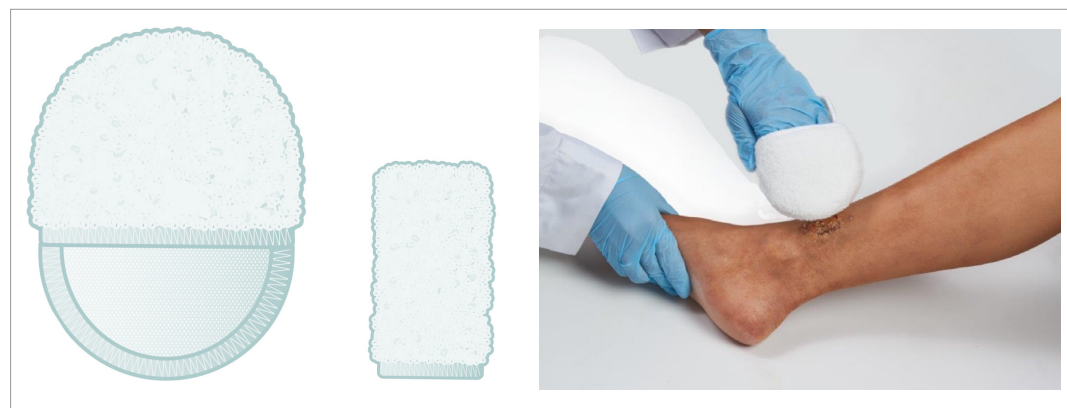Kliniderm debride has an intuitive design: it is double-sided and fits onto a gloved hand, enabling manoeuvrability and allowing control during debridement. During debridement, slough, hyperkeratosis, debris, biofilms and devitalised cells are bound in the fibre composite and thereby

removed from the wound and surrounding skin.

The key features of Kliniderm debride are:

- ▶▶ Double-sided, enabling both the wound and the surrounding skin to be managed in a single treatment
- ▶▶ Quick and effective wound debridement method
- ▶▶ Safe, polyester fibres that don't shed
- ▶▶ Gently removes devitalised tissue, debris and hyperkeratosis
- ▶▶ Unique pressure application control
- ▶▶ Simple application with immediate results
- ▶▶ Versatile and easy-to-use, so can be used in hospital, clinic, or community settings
- ▶▶ Minimal pain caused
- ▶▶ Cost-effective.

Kliniderm debride is suitable for the treatment



**Figure 3. Kliniderm debride**

of superficial acute and chronic wounds and the surrounding skin of diabetic foot ulcers, leg ulcers, pressure ulcers and post-operative wounds healing by secondary intention, lacerations and abrasions, burns, scalds and lymphoedema.

The product is available as a mitten and as a 'pocket' version, which is placed over a finger, allowing debridement and even more control for smaller wounds (*Figure 3*). It can be used in any healthcare setting and is safe to use by less experienced practitioners and by patients or their carers. Follow manufacturer's directions for use on pre-soaking and application, and ensure a new pad is used for every separate wound to reduce risk of cross-contamination.

**METHOD**

Since 2016, The Skin Integrity Team at Doncaster and Bassetlaw Teaching Hospitals NHS Foundation Trust have used the Pathway for Wound Cleansing (*Figure 2*). A review of the evidence-based practice around wound bed preparation had showed that cleansing and debriding at each wound assessment reduced the number of reported wound infections and the clinical need for antibiotic use. This has since been updated to include mechanical debridement and, since 2019, been implemented across the Doncaster Wound Care Alliance, covering both acute and secondary care.

All wounds that have been present for more than 14 days, or when the wound and/or patient has a high risk factor for wound infection receives a 10-minute wound and periwound cleanse using a wound irrigation solution that combines

Polyhexanide and Betaine. Following cleansing, each wound is then considered for mechanical debridement.

An evaluation was conducted on Kliniderm debride and Kliniderm debride pocket across 23 wounds in the Skin Integrity Complex Wound Clinic, comparing product usage to the current debridement product used. Kliniderm debride and Kliniderm debride pocket were used, along with the currently used wound irrigation solution, at each clinic dressing change. Whenever patients were reviewed in the Skin Integrity Complex Wound Clinic, the Kliniderm debride and Kliniderm debride pocket were used; however, it should be noted that the patients may have had wound debridement completed in other settings as per the current Pathway for Wound Cleansing, where the patient was receiving shared care across the Doncaster Wound Care Alliance.

**RESULTS**

The evaluation included 23 wounds and was completed over a period of 1 to 11 weeks (average 4 weeks), with the number of debridements ranging from one debridement to a maximum of 5 over the evaluation period. 59% (n=13) of patients were already receiving debridement as per the current pathway for wound cleansing.

The patients included 17 males and 5 females, with 55% of patients being over 70 years of age. The patients' wound type/diagnosis varied, with the majority being surgical wounds and leg ulcers: 30% (n=7) surgical wounds, 30% (n=7) leg ulcers and 17% (n=4) dehisced surgical wounds (see *Figure 4* for more detailed information). The patients' wound

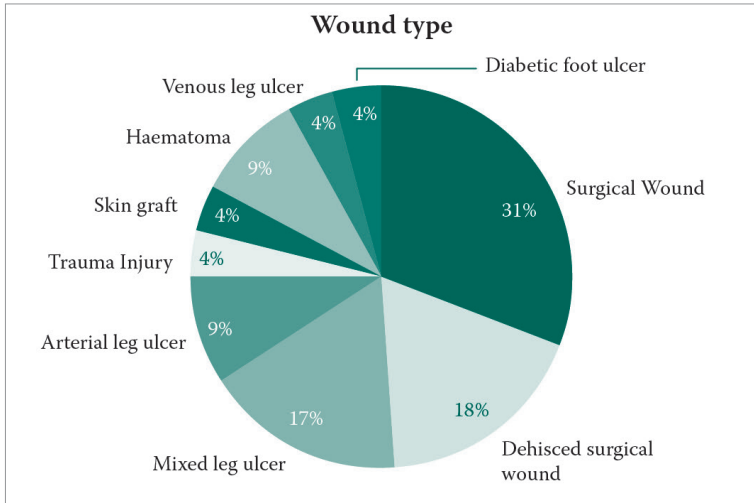


Figure 4. Wound types (percentages have been rounded up to whole numbers)

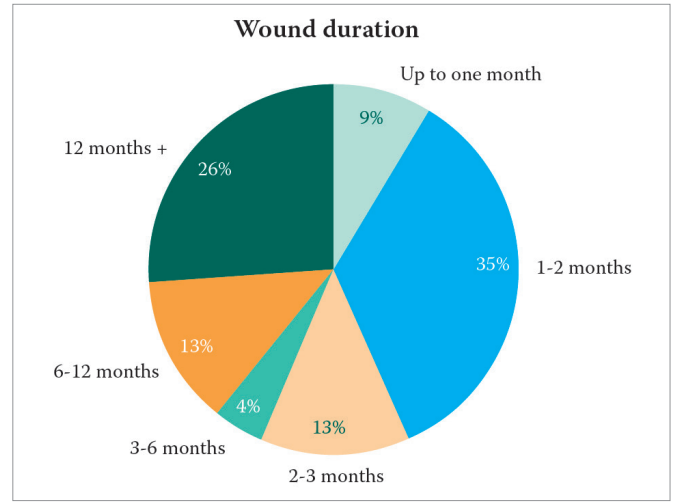


Figure 5. Wound duration

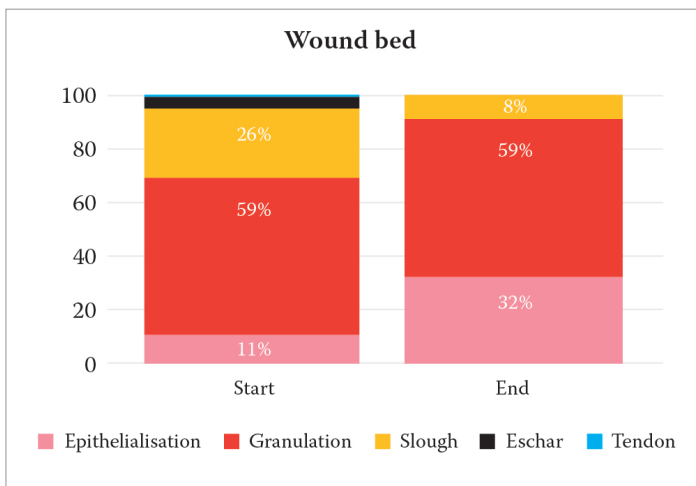


Figure 6. Tissue changes to wounds from start to finish of evaluation

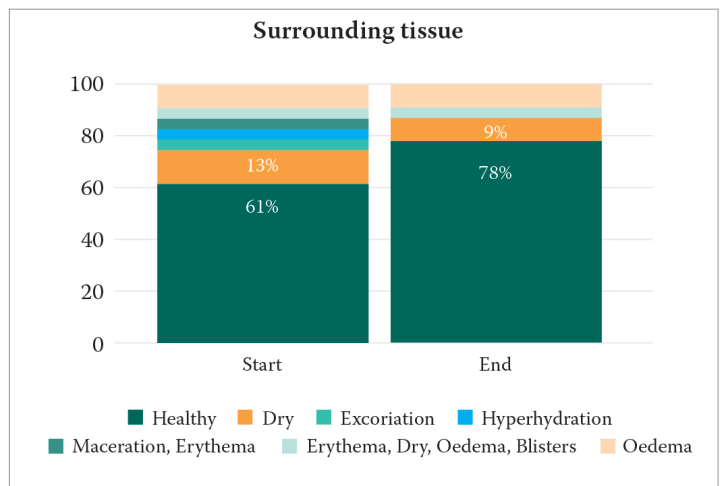


Figure 7. Changes to the surrounding tissue from start to finish of the evaluation

duration also varied from up to one week to over 10 years, with 39% (n=9) wounds having a duration of over 6 months (Figure 5).

The baseline assessment (n=23) wounds information at the start of the evaluation was as follows:

- ▶ Tissue type assessment: 11% epithelialisation; 59% granulation; 26% sloughy; 4% eschar; 0.4% tendon
- ▶ The surrounding skin assessment: 61% (n=14) healthy; 13% (n=3) dry; 9% (n=2) oedema; 4% (n=1) hyper-hydration; the remaining 12% (n=3) maceration, erythema or excoriation
- ▶ The wound sizes ranged from 0.3 x 1.7cm to 18 x 12cm (0.5cm<sup>2</sup> to 216cm<sup>2</sup>) with an average of 36cm<sup>2</sup>, with the depth ranging from unknown to 0.5cm

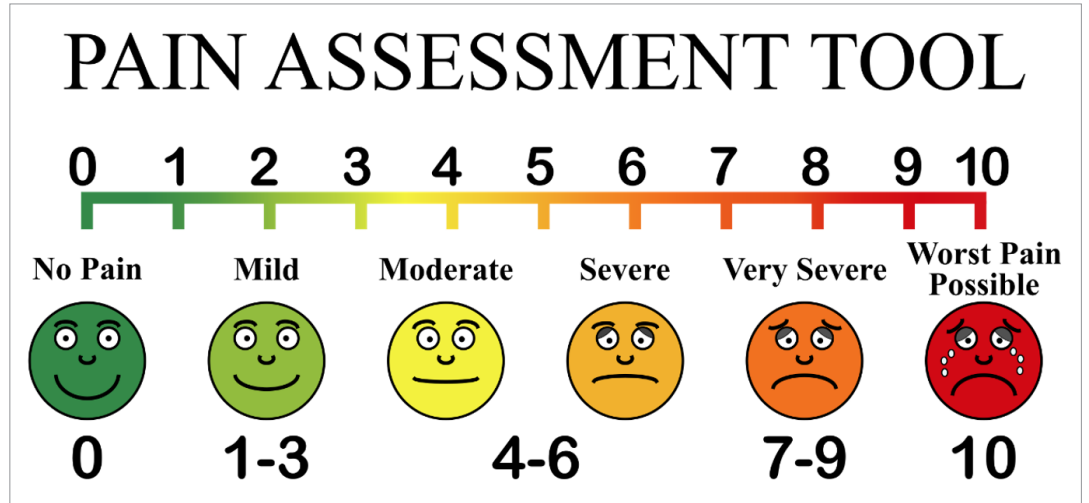
- ▶ At the start of the evaluation, 9% (n=2) wounds reported pain before debridement and 13% (n=3) patients had reported pain with the previously used debridement product.

The assessment information at the end of the evaluation was as follows:

- ▶ The wound sizes at the end of the evaluation ranged from 0.6 to 216cm<sup>2</sup>, with an average of 24cm<sup>2</sup>, showing a reduction of 33% across all wounds; however, when reviewing the 74% (n=17) of wounds which received more than one debridement, the wound area reduction was 56% over the evaluation period
- ▶ The tissue assessment showed positive changes, with epithelialisation increasing from 11% to 32%,



Figure 8. The pain assessment tool



granulation at 59%, slough reducing from 26% to 8%, and eschar from 4% to 0% (Figure 6)

- ▶ At the start of the study, the surrounding tissue was healthy in 61% (n=14), which increased to 78% (n=18) by the end of the evaluation (Figure 7).
- ▶ From the tissue type comparative data, it can be deemed that the Kliniderm debride and Kliniderm debride pocket were effective at debriding the wound in 96% (n=22) of wounds. The surgical wound that did not achieve the required debridement was referred for surgical debridement.

Pain was assessed using the scale: 0 – No pain; 5 – Moderate pain; 10 – Worst pain possible (Figure 8). In 17% (n=4) of wounds, the patients experienced mild pain during debridement ranging from 1 to 3 and 9% (n=2) patients reported mild pain post-debridement. However, 83% (n=19) experienced no pain before, during or post-debridement with Kliniderm debride products.

A scale of 1–10 was used to record the products' ease of use, with 1 being poor and 10 being excellent. Kliniderm debride and Kliniderm debride pocket were rated by clinicians as: 61% (n=14) excellent, with the remaining 39% (n=9) scoring 8 or 9 (Figure 9). In addition, the clinicians reported that Kliniderm debride and Kliniderm debride pocket were appropriately sized for debridement for 22 of 23 wounds; for one wound, both of the products were too large, as this was a patient that had a non-healing spinal wound that was very narrow in width and length. There was a 100% satisfaction rate with Kliniderm debride versus other debridement products, and in 96% (n=22) of the wounds, clinicians said

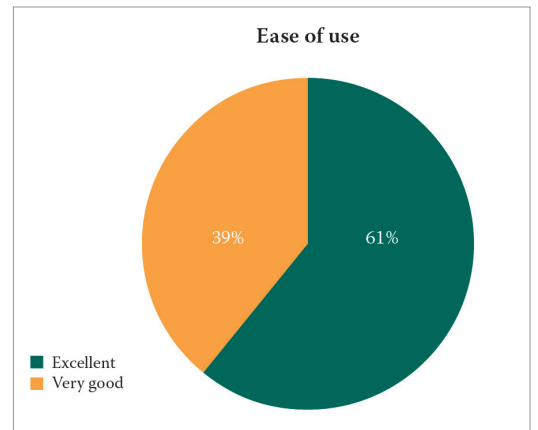


Figure 9. Product ease of use

they would recommend the product for future use (Table 2).

Additional clinical performance feedback can be seen (Table 3). Patient experience was also measured, with 96% (n=21) patients rating their experience with the products as 'good' or 'excellent', with only one patient stating their experience was satisfactory (additional patient feedback can be seen in Table 4).

**CASE STUDIES**

The following case studies illustrate individual patients and their experience throughout the evaluation of Kliniderm debride and Kliniderm debride pocket, plus product feedback from the clinicians. All wounds were assessed pre- and post-debridement using the TIMES assessment framework.

**Patient 1**

A 61-year-old gentleman was seen in the complex

**Table 2: Would clinicians recommend Kliniderm debride for future use?**

Would you recommend use of Kliniderm debride	Kliniderm debride	Kliniderm pocket	
No		1	4%
Yes	9	13	96%

**Table 3. Clinical performance feedback**

Pros	Cons
Works well on periwound skin where previous debridement product struggled	Too bulky/large for narrow wound
Debrided slough and dry skin well	Some signs of haemoserous exudate following debridement
Previously struggled to remove dull tissue, minimal use of Kliniderm for removal of dull tissue to reveal healthy granulation	
Impressed with debridement of wound bed and periwound skin, improvement of venous eczema	
Removed build-up of other products from wound bed	
Biofilm presentation on static leg ulcers removed with debridement	
Worked well to remove dry periwound skin	
Fibrous slough was softened with debridement	
Improved granulation tissue	
Effective removal of dried skin and slough	

**Table 4. Patient feedback**

Pros	Cons
Patient tolerated well with no complaints of pain	Was still very painful but happy with results and wound bed appearance (VAS score 3)
No complaints of discomfort	
Patient found it soothing	
Patient felt no pain	

wound clinic with a haematoma to the left lower leg, which had been present for 2 months. The patient had a past medical history of peripheral arterial disease

On initial assessment he presented with: T = 70% granulation, 30% slough; I = no signs of infection or inflammation; M = minimal serous straw-coloured exudate; E = 4 x 5cm (0.5cm depth); S = healthy surrounding skin.

The patient received five wound assessments over a 5-week period, including debridement at each assessment with Kliniderm debride pocket. During each assessment, tissue types were 100% healthy tissue and the skin remained healthy through the evaluation. At the end of evaluation: T = 100% granulation; I = no signs of infection or inflammation; M = minimal serous straw-coloured exudate; E = 1 x 4cm (0.1cm depth); S = healthy surrounding skin.

The product was effective at debriding the wound bed and prevented build-up of biofilm, leading to wound healing. There were no reports of pain during or after debridement. The clinician feedback was excellent, with the product reported as easy to use, and an appropriate shape and size. The specific feedback from the clinicians was that the debridement product was effective in the removal of the primary dressing, which was a hydrogel that creates a hard shell over the wound bed. The debridement pad effectively lifted this at each wound assessment.

**Patient 2**

This patient was a 38-year-old female with a past medical history of intravenous drug use. She presented in the complex wound clinic with chronic venous leg ulceration to the left leg, which had been

Patient 3: Before debridement

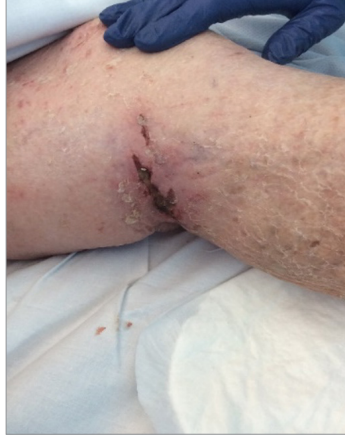

Figure 10. Trauma wound left knee initial assessment

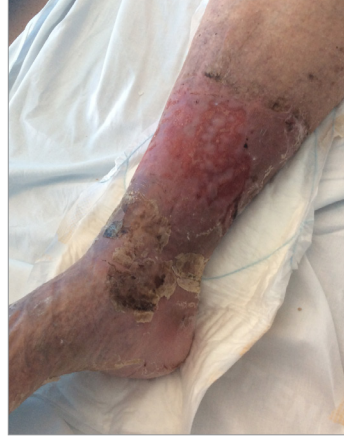

Figure 11. Right leg mixed leg ulcer on presentation

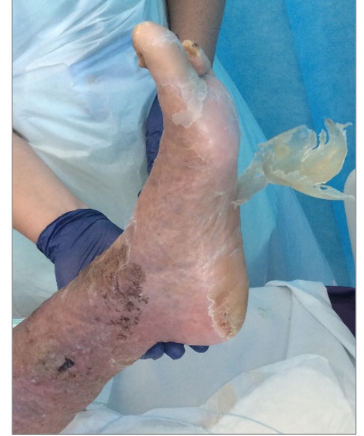

Figure 12. Left foot initial assessment

Patient 3: Post-debridement

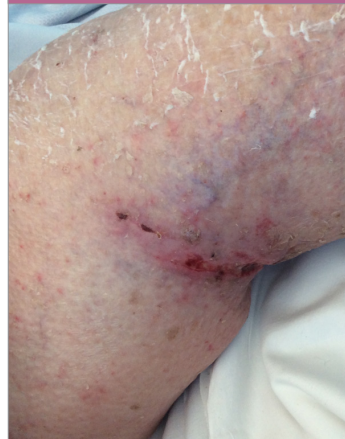

Figure 13. Trauma wound left knee post-debridement

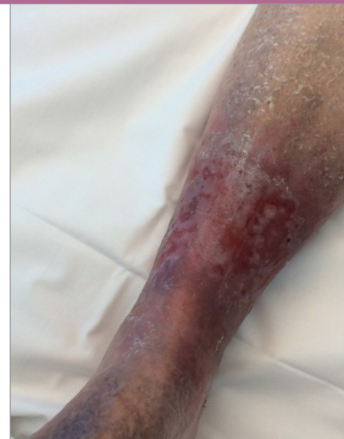

Figure 14. Right leg mixed leg ulcer post-debridement

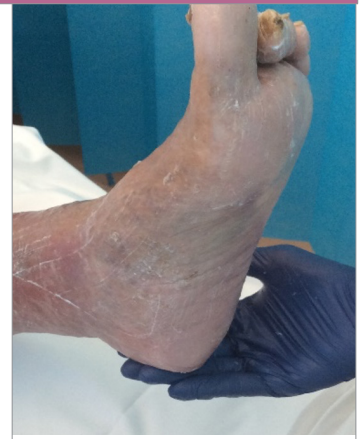

Figure 15. Left foot post-debridement

present for 18 months. The patient had been self-caring with appropriate compression hosiery and had received wound debridement with the use of another debridement pad prior to the evaluation of Kliniderm debride. On initial wound assessment: T = 80% granulation, 20% slough; I = no signs of infection or inflammation; M = moderate serous straw-coloured exudate; E = 6 x 5cm (0.2cm depth) S = healthy surrounding skin.

The patient was seen twice-weekly during evaluation with Kliniderm debride, with each assessment recorded after debridement. After two debridements, the wound continued to have a 10% presentation of slough; however, the wound continued to reduce in size and the tissue types changed. The last assessment was recorded: T= 10% epithelisation, 90%

granulation; I = no signs of infection or inflammation; M = minimal serous exudate; E = 5 x 5cm (0.1cm depth); S = healthy surrounding skin.

The patient reported the debridement to be enjoyable and found it soothing on the wound and periwound skin. The clinicians scored the ease of product use as excellent, finding it favourable in comparison to other debridement products, and would recommend to others.

**Patient 3**

An 88-year-old lady was admitted to the acute setting not relating to wounds. She had a past medical history of contact dermatitis and atrial fibrillation, and presented with a leg ulcer of mixed disease to the right lower leg, which had been present for 18 months, and



a trauma wound to left medial knee. Her wound care had previously been conducted by her family and did not involve the use of debridement (see Figures 10–12 for images of the wound pre-debridement).

Trauma wound to the left knee assessed prior to debridement: T = 100% eschar; I = no signs of infection or inflammation; M = none; E = 1 x 5cm (depth unknown); S = dry surrounding skin. Post-debridement: T = 80% granulation, 20% slough; I = none; E = 1 x 5cm (0.3cm depth); S = healthy surrounding skin.

Mixed leg ulcer to the right leg assessed prior to debridement: T = 20% epithelialisation, 50% granulation, 30% slough; I = no signs of infection or inflammation; M = minimal exudate; E = 18 x 12cm (depth unknown); S = dry surrounding skin, oedema present. Post-debridement: T = 70% epithelialisation, 30% granulation; I = no signs of infection or inflammation; M = minimal exudate; E = 18 x 12cm (depth 0.1cm); S = healthy surrounding skin, oedema present.

After one cleanse and debridement using the Kliniderm debride pocket, the wound bed improved on both wounds (see Figures 13–15). All eschar was removed for the left leg trauma wound and there was a significant improvement in the periwound skin on both lower limbs. The Kliniderm debride pocket effectively removed thick and dry hyperkeratosis without causing trauma, to reveal healthy epithelialisation tissue. The patient did report mild pain during the debridement process, but was comfortable enough to continue with the process. The patient was amazed with the results and the clinician was able to use distraction techniques effectively from the mild pain reported. The product was easy to use and excellent results were recorded.

### CONCLUSION

Having been used in 22 patients and 23 wounds, it was deemed that Kliniderm debride and Kliniderm debride pocket were effective at debriding a wound when compared to the previous mechanical debridement pad used. For 96% of wounds treated, the clinicians would recommend these products to other clinicians working in the field of wound care. During the evaluation there were improvements in wound volume, tissue and surrounding skin. However, it must be noted that the Kliniderm debride and Kliniderm debride pocket were both used in conjunction with wound cleansing using a wound

irrigation solution that combines Polyhexanide and Betaine, as per the Trust protocol.

Both the Kliniderm debride and Kliniderm debride pocket products were found to be easy to use and were effective in the removal of devitalised tissue and the removal of hyperkeratosis. The products were reported as being soft on the skin but efficient and effective in reducing bacterial load and removing biofilm from the wound bed. The products are recommended for use as part of effective wound bed preparation. WUK

### REFERENCES

- Anghel EL, Defazio MV, Baker JC et al (2016) Current Concepts in debridement: Science and Strategies. *Plast Reconstr Surg* 138(3Suppl):825-93S
- Ayello EA, Cuddigan JE (2004) Debridement: controlling the necrotic/cellular burden. *Adv Skin Wound Care* 17(2):66-75
- Davies CE, Woolfrey G, Hogg N et al (2015) Maggots as a wound debridement agent for chronic venous ulcers under graduated compression bandages: A randomised control trial. *Phlebology* 30(10):693-9
- Falanga V (2000) Classifications for wound bed preparation and stimulation of chronic wounds. *Wound Repair Regen* 8(5):347-52
- Gray D, Action C, Chadwick P et al (2011) Consensus guidance for the use of debridement techniques in the UK. *Wounds UK* 7(1):77-84
- Kubo M, Vander Water L, Plantefaber LC et al (2001) Fibrogen and fibrin are anti-adhesive for keratinocytes: a mechanism for fibrin, eschar and slough during wound repair. *J Invest Dermatol* 117(6):1369-81
- Leaper D (2002) Surgical debridement. Available at: [www.worldwidewounds.com/2002/december/Leaper/Sharp-Debridement.html](http://www.worldwidewounds.com/2002/december/Leaper/Sharp-Debridement.html) (accessed 15.08.2022)
- O'Brien J (2003) Debridement: ethical, legal and practical considerations. *Br J Comm Nurs* 8(Suppl 3):23-5
- O'Brien M (2002) Exploring methods of wound debridement. *Br J Comm Nurs* 10:12, 10-18
- Percival SL, Suleman L (2015) Slough and biofilm: removal of barriers to wound healing by desloughing. *J Wound Care* 24(11):498, 500-3, 506-10
- Reid J, Morrison M (1994) Towards a consensus: classification of pressure ulcers. *J Wound Care* 3(3):157-60
- Schultz GS, Sibbald RG, Falanga V et al (2003) Wound bed preparation: a systematic approach to wound management. *Wound Repair Regen* 11:S1-28
- Strohler IR, Apelqvist J, Dissemont J et al (2013) EWMA document: debridement. An updated overview and clarification of principle role of debridement. *J Wound Care* 22:S1-52
- Vowden KR, Vowden P (1999) Wound debridement. *J Wound Care* 8(5):237-40
- Weir D, Scarborough P, Niezgodaj A (2007) Wound debridement. In: Krasner DL, Rodeheaver GT, Sibbald RG (eds) *Chronic Wound Care: 4th edn*. HMP Communications, Malvern: 343-55
- Wilcox JR, Carter MJ, Covington S (2013) Frequency of debridements and time to heal: a retrospective cohort study of 312744 wounds. *JAMA Dermatol* 149(9):1050-8
- Wolcott RD, Kennedy JP, Dowd SE (2009) Regular debridement is the main tool for maintaining a healthy wound bed in most chronic wounds. *J Wound Care* 18(2):54-6
- Wolcott RD, Rumbaugh KP, James G et al (2010) Biofilm maturity studies indicate sharp debridement opens a time dependent therapeutic window. *J Wound Care* 19(8):320-8
- Wounds UK (2016) Best Practice Statement: Holistic management of venous ulceration

### ACKNOWLEDGEMENTS

The Skin Integrity Team, Doncaster and Bassetlaw Teaching Hospitals NHS Foundation Trust.

### DECLARATION OF INTEREST

The products were supplied by the company free of charge.