

HydroTherapy

made easy

Box 2: Versions of HydroClean® plus

HydroClean® plus

Suitable for the treatment of the majority of acute and chronic superficial wounds, where moist wound healing is required. The dressing is suitable for the cleansing and granulation phase of healing. Its unique cleanse-absorb mechanism removes necrosis, fibrinous material, bacteria and exudate, trapping them within the dressing. The presence of silicone strips on the wound-contacting side of the dressing minimises dressing-induced tissue trauma and the experience of pain during dressing change is reduced.

HydroClean® plus Cavity

Suitable for deep wounds and/or cavities. It can be effectively packed into deep wounds or cavities due to the dressing's uniformity on all sides.

Box 3: How HydroTac® works

A. Wound exudate and the damaging exudate components (red stars) are taken up by the foam layer (red arrow).



B. The hydrating action of patented AquaClear Technology releases fluid (blue arrow) to optimise hydration levels within the wound bed.



C. Optimisation of hydration levels and growth factor concentration action of AquaClear Technology leads to new granulation tissue formation and associated epithelialisation.



Box 4: Versions of HydroTac®

HydroTac®

Suitable for the treatment of the majority of acute and chronic wounds in the granulation and epithelialisation phases of healing, and with low to moderate exudation. The presence of silicone strips on the wound-contacting side of the dressing minimises dressing-induced tissue trauma and the experience of pain during dressing change is reduced.

HydroTac® comfort

Has the added feature of a self-adhesive border making the dressing showerproof.

HydroTac® sacral

The specific shape of HydroTac® sacral makes it suitable for treatment in the sacral region. It also features a self-adhesive border.

CASE STUDY 1. PRESSURE ULCER WITH 100% NECROSIS

A 95-year old patient with a pressure ulcer. The wound was located on the left heel and had been present for 2 weeks. On presentation, the wound showed 100% coverage with necrotic tissue (Figure A).

Treatment

The aim of treatment was to remove the devitalised tissue quickly, prepare the wound bed, promote healthy granulation tissue and facilitate wound closure. HydroClean® plus was applied and secured with a film dressing. Once the wound was cleaned and healthy granulation tissue covered the wound bed, HydroTac® was used to promote the latter stages of wound healing. Dressings were changed every 3-4 days.

Outcomes

After 4 days of treatment with HydroClean® plus, the wound base was largely clear of devitalised tissue (Figure B) and by the 3rd dressing change (treatment day 7), new and healthy granulation tissue was visible and normalisation of the wound environment had progressed. Upon the development of healthy granulation tissue, the treatment dressing was changed to HydroTac®. Over the course of the following 4 weeks, epithelialisation of the wound was rapid and the size of the wound reduced significantly. By the conclusion of the observation period, only a small open wound remained (Figure C).

CASE STUDY 2. LEG ULCER WITH TENDON EXPOSURE

A 91-year-old lady had a leg ulcer exposed to the tendon due to vascular insufficiency (Figure A). The wound measured 11.5cm x 10.5 cm and comprised 30% slough and 70% granulation tissue. The wound was too painful to tolerate compression therapy, and the patient had moderate exudate and fragile and dry periwound skin.

Treatment

The wound was too painful to tolerate compression therapy, and the patient had moderate exudate and fragile and dry periwound skin. HydroTac was introduced to the treatment strategy due to poor healing.

Outcomes

After just 7 days of treatment with HydroTac, the wound showed a reduction in size and the condition of the wound bed had improved; at 14 days there was a reduction in tendon exposure and granulation tissue was beginning to cover the wound. After 21 days of treatment, there was a minimum amount of tendon exposed and a healthy wound bed (Figure B).

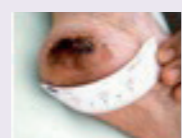

Figure A. Wound prior to treatment with HydroClean® plus

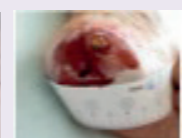

Figure B. Day 4: second dressing change after start of HydroClean® plus treatment

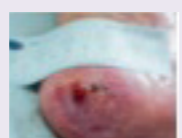

Figure C. Week 8: 16th dressing change after HydroClean® plus and HydroTac® treatment



Figure A. Wound prior to treatment with HydroTac®

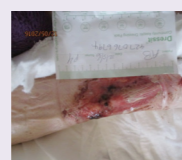

Figure B. Day 21 of treatment with HydroTac®

Clinical evidence for HydroTherapy derives from a number of studies, including a 75-patient, multicentre, open and randomised study; a 403-patient observational study; a 221-patient observational study; a 20-patient community-based study; and a number of case series studies (Ousey et al, 2016b). HydroClean® plus and HydroTac® have been evaluated in terms of debridement and wound cleansing, bacterial sequestration, managing wound exudate and protecting the wound edge, and the impact of patients' quality of life (Table 3).

SUMMARY

HydroTherapy is a simple, effective and innovative approach to the treatment of a variety of wounds, which combines the benefits of two complementary wound dressings to optimise hydration levels at all stages of the healing process. Together, HydroClean® plus, via its patented rinsing and absorbing action, and HydroTac®, which maintains optimal hydration levels and promotes epithelialisation, stimulate wound progression and healing.

REFERENCES

Bishop SM, Walker M, Rogers AA, et al (2003) Importance of moisture balance at the wound-dressing interface. *J Wound Care* 12(4): 125-8

Bruggisser R (2005) Bacterial and fungal absorption properties of a hydrogel dressing with a superabsorbent polymer core. *J Wound Care* 14(9): 438-42

Chen WJY, Rogers AA (2007) Recent insights into the causes of chronic leg ulceration in venous diseases and implications on other types of chronic wounds. *Wound Repair Regen* 15(4): 434-49

Colegrave M, Rippon MG, Richardson C (2016) The effect of Ringer's solution within a dressing to elicit pain relief. *J Wound Care* 25(4): 184-90

Dowsett C, Newton H (2005) Wound bed preparation: TIME in practice. *Wounds UK* 1(3): 58-70

Eming S, Smola H, Hartmann B, et al (2008) The inhibition of matrix metalloproteinase activity in chronic wounds by a polyacrylate superabsorber. *Biomaterials* 29(19): 2832-40

EWMA (European Wound Management Association). *Position Document: Hard-to-heal wounds: a holistic approach*. London: MEP Ltd, 2008

HARTMANN (2010) *Effective wound cleansing with TenderWet active – observational study with 403 patients*. Available at: http://nl.hartmann.info/images/20140219_observatie_studie.pdf (accessed 18 August 2016)

Humbert P, Favière B, Vêran Y, et al (2014) Protease modulating polyacrylate-based hydrogel stimulates wound bed preparation in venous leg ulcers – a randomized controlled trial. *J Eur Acad Dermatol Venereol* 28(12): 1742-50

Junker JP, Kamel RA, Caterson EJ, et al (2013) Clinical impact upon wound healing and inflammation in moist, wet, and dry environments. *Adv Wound Care (New Rochelle)* 2(7): 348-56

Kaspar D (2011) TenderWet plus. *Therapeutic effectiveness, compatibility and handling in the daily routine of hospitals or physician's practices*. Published by HARTMANN

Kaspar D, Dehiri H, Tholon N, et al (2008) Efficacité clinique du pansement irrigo-absorbant HydroClean actif contenant du polyacrylate superabsorbant dans le

traitement des plaies chroniques – étude observationnelle conduite sur 221 patients. *J Plaies Cicatrisations* 13(63): 21-4

Knestele M (2004) The treatment of problematic wounds with TenderWet – tried and tested over many years in clinical practice. *WundForum Special Issue*: 3

König M, Vanscheidt W, Augustin M, et al (2005) Enzymatic versus autolytic debridement of chronic leg ulcers: a prospective randomised trial. *J Wound Care* 14(7): 320-3

Leaper DJ, Schultz G, Carville K, et al (2012) Extending the TIME concept: what have we learned in the past 10 years? *Int Wound J* 9(Suppl. 2): 1-9

Li J, Chen J, Kirsner R (2007) Pathophysiology of acute wound healing. *Clin Dermatol* 25(1): 9-18

Ousey K, Cutting KF, Rogers AA, et al (2016a) The importance of hydration in wound healing: reinvigorating the clinical perspective. *J Wound Care* 25(3): 122-30

Ousey K, Rogers AA, Rippon MG (2016b) HydroClean® plus: a new perspective to wound cleansing and debridement. *Wounds UK* 12(1): 94-104

Rippon MG, Ousey K, Cutting KF (2016) Wound healing and hyper-hydration: a counterintuitive model. *J Wound Care* 25(2): 68-75

Scherer R, Kägi M, Geiges R et al (2015) *HydroTherapy*. Application study. Published by HARTMANN

Scholz S, Rompel R, Petres J (1999) A new approach to wet therapy of chronic leg ulcers. *Arzt Praxis* 53(816): 517-22

Schultz G, Sibbald G, Falanga V, et al (2003) Wound bed preparation: a systematic approach to wound management. *Wound Rep Regen* 11(Suppl. 1): 1-28

Smola H, Maier G, Junginger M, et al (2014) *Hydrated polyurethane polymers to increase growth factor bioavailability in wound healing*. Presented at the European Orthopaedic Research Society symposium, Nantes, France

Smola H, Maier G, Junginger M, et al (2016a) *Hydrated polyurethane polymers to increase growth factor bioavailability in wound healing*. Presented at HydroTherapy: A New Perspective on Wound Cleansing, Debridement and Healing symposium, London UK

Smola H, Zöllner P, Ellermann J, et al (2016b) *From material science to clinical application – a novel foam dressing for the treatment of granulating wounds*. Presented at the HydroTherapy: A New Perspective on Wound Cleansing, Debridement and Healing symposium, London UK

Spruce P, Bullough L, Johnson S, et al (2016) Benefits of HydroClean® Plus in wound bed preparation: a case study series. *Wounds International* 7(1): 26-32

WUWHS (World Union of Wound Healing Societies). *Principles of best practice: Wound exudate and the role of dressings*. A consensus document. London: MEP Ltd, 2007

AUTHOR DETAILS

Ousey K, Rippon MG², Rogers AA³

1. Karen Ousey, PhD, Professor and Director for the Institute of Skin Integrity and Infection Prevention, School of Human and Health Sciences, University of Huddersfield, Queensgate, West Yorkshire, UK
2. Mark G. Rippon, PhD, Visiting Clinical Research Fellow, School of Human and Health Sciences, University of Huddersfield, Queensgate, West Yorkshire, UK
3. Alan A Rogers, BSc (Hons), Independent Wound Care Consultant, Flintshire, UK

Introduction

Rapid cleansing, early granulation and sustained epithelialisation are key requirements for the efficient healing of chronic wounds and wounds with impaired healing. Wound bed preparation offers a systematic framework to aid clinicians in their goal of progressing wounds from impairment to healing. This Made Easy discusses HydroTherapy (HARTMANN), an innovative approach to the treatment of wounds, where a harmonised, two-step therapy harnesses optimised hydration at all stages of the healing response to promote wound progression and healing.

Authors: Ousey K, Rippon MG, Rogers AA. Full author details can be found on page 6.

WHY ARE SOME WOUNDS DIFFICULT TO HEAL?

Normal wound healing progresses through a series of interdependent overlapping steps; it includes the phases of inflammation, granulation tissue formation and epithelialisation (Li et al, 2007). As well as playing a role in cleaning the wound bed of contaminating bacteria and tissue debris, inflammation plays a pivotal role in initiating the subsequent phases of the healing response. Each phase of normal wound progression is interdependent; as such, if progression does not proceed normally in any phase, healing will be affected (Chen and Rogers, 2007).

Wounds may become chronic as a result of becoming stuck in the inflammatory phase. 'Stalled' healing in chronic wounds can result from a number of factors. Underlying medical conditions (e.g. vascular disease, diabetes) play a role in initiating elevated and sustained inflammation that leads to tissue breakdown and an interrupted wound healing response (Chen and Rogers, 2007). Local tissue factors such as the status of the wound (e.g. level of inflammation) also result in delayed healing. The presence of devitalised tissue, excessive exudate production and a high bioburden contribute to maintaining a high level of tissue inflammation and inhibit healing (WUWHS, 2007; EWMA, 2008).

THE IMPORTANCE OF WOUND BED PREPARATION

Wound bed preparation (WBP) is an essential component of wound management (Schultz et al, 2003). As part of a formalised framework of guidelines, WBP is an important systematic approach to aid wound progression by promoting the removal of the main physical barrier to wound healing – wound bed surface devitalised tissue (including necrosis and slough) (Dowsett and Newton, 2005).

The TIME management framework is a practical assessment tool to aid in the identification of barriers to the progression of wound healing (Schultz et al, 2003; Leaper et al, 2012). TIME leads to the implementation of a treatment plan that stimulates wound healing. The four main components of TIME are tissue management (T), control of infection and inflammation (I), moisture imbalance (M), and the advancement of the epithelial edge (epithelialisation) (E) (Schultz et al, 2003; Leaper et al, 2012), and are key to effective wound bed preparation and wound healing (Table 1).

Table 1. Summary of TIME components

	Clinical requirement	Clinical action
T	Tissue management	WBP to remove non-viable tissue and foreign material
I	Control of infection and inflammation	Remove infection and prevent excessive and uncontrolled inflammation
M	Moisture balance	Remove excess wound exudate and establish moist wound environment
E	Advancement of epithelial edge of the wound	Provide an optimal environment for wound closure

THE IMPORTANCE OF A MOIST WOUND-HEALING ENVIRONMENT

The optimal level of hydration required to support wound healing has yet to be determined (Bishop et al, 2003). However, since the key studies of George Winter in the early 1960s, it has been known that the establishment of a moist wound environment aids wound healing (Table 2). Occlusive/semi-occlusive, moisture-retentive dressings over wounds create a moist wound environment that is optimal for wound healing via the benefits noted in Table 2. The moist environment allows for ideal conditions for the cellular processes necessary for wound healing to proceed and removes the barriers that delay the healing response.

The development of modern, advanced wound dressings that are designed to manage wound exudate, optimise tissue hydration levels and provide a moist wound environment has been significant in recent years and represents an important advance for healing for both patient and clinician (Ousey et al, 2016a). The establishment of a moist wound environment by advanced wound dressings promotes the required actions necessary to advance healing as set out in the TIME framework (Table 1).

Maceration of the periwound skin is considered to be the result of excessive tissue hydration and has significant adverse effects on tissues in and around the wound bed (Cutting, 1999). However, studies have shown that prolonged exposure of skin to moisture does not necessarily lead to tissue maceration (Junker et al, 2013; Rippon

Table 2. Wound bed preparation: TIME in practice (adapted from Dowsett, 2005)
Faster wound healing
Promotion of epithelialisation
Promotion of granulation tissue formation
Reduced scarring
Retention of growth-promoting factors within the wound
Lower infection rates
Reduction of pain perception
Enhanced autolytic debridement

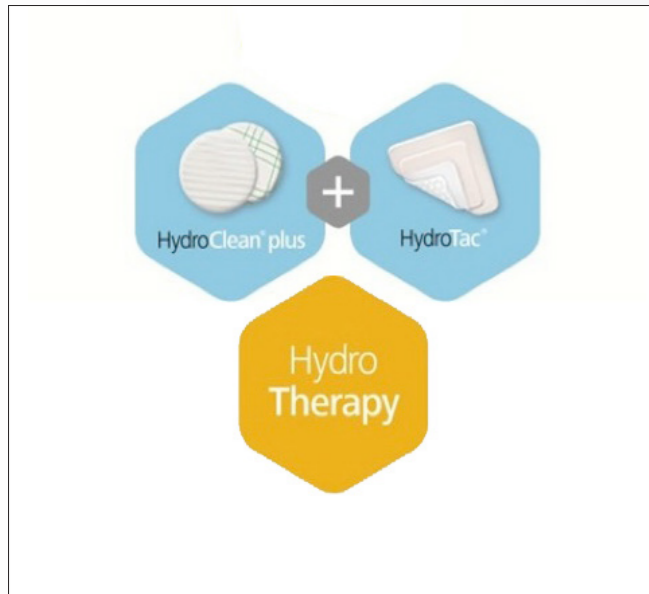


Figure 1. What is HydroTherapy?




Figure 2. How does HydroTherapy work?

et al, 2016). The evidence suggests that the elevated destructive biological components found in chronic wound exudate are responsible for tissue maceration (Rippon et al, 2016). Wounds exposed to free fluid (e.g. wounds covered with chambers into which saline is added) appear to benefit from many of the positive aspects of moist wound healing (Junker et al, 2013). The hyperhydration of wounds, whereby tissue is hydrated beyond what is a normally acceptable therapeutic level (e.g. in moist wound healing), has recently been proposed as a therapy for a variety of wounds (Rippon et al, 2016). The use of isotonic fluids in hyperhydration, the skin's ability to recover quickly from the effects of exposure to free fluid and the control by wound dressings of excessive proteolytic activity in chronic wound exudate combine to support healing.

WHAT IS HYDROTHERAPY?

HydroTherapy is a sequential wound treatment programme that delivers simple and effective wound care, whatever the wound type. Through the use of two innovative and complementary wound dressings (HydroClean® plus and HydroTac®) (Figure 1), HydroTherapy supports the healing process from the cleansing phase (start of treatment) through to epithelialisation (healed wound) (Figure 2).

HydroClean® plus

HydroClean® plus is a Hydro-Responsive Wound Dressing (HRWD) that cleanses, debrides, desloughs and absorbs. The dressing comprises a soft and comfortable pad, which contains a Hydro-Responsive matrix at its core. Superabsorbent polyacrylate (SAP) particles containing Ringer's solution form part of the matrix and provide a continuous rinsing and absorption effect for supporting effective wound bed preparation. Ringer's solution is an isotonic salt solution that is balanced relative to the body's fluids that has been reported to have clinical benefits (Colegrave et al, 2016). Pre-activation of the SAP with Ringer's solution allows for rapid and sustained cleansing of the wound bed (König et al, 2005; Humbert et al, 2014; Spruce et al, 2016).

HydroTac®

HydroTac® is a HRWD with AquaClear Technology. The dressing is made up of a hydrogel wound contact layer, covered by a foam, with an air-permeable, waterproof and bacteria-proof film backing. The wound side of the dressing features AquaClear

Technology that actively releases moisture. AquaClear Technology is designed to increase growth factor concentration, thus speeding up epithelial wound closure.

HydroTherapy is based on the use of two innovative wound dressings each with a special mode of action. Complementing one another, HydroClean® plus and HydroTac® optimise hydration levels at all phases of the healing response, supporting granulation tissue formation and wound closure via epithelialisation (Table 3) (Ousey et al, 2016b).

HydroClean® plus

HydroClean® plus is an ideal first step in wound bed preparation and healing. The dressing offers a patented Rinsing-Absorption mechanism that softens and removes devitalised wound tissues such as necrosis and absorbs excessive wound exudate (Figure 3). Ringer's solution, contained within the SAP particles, is donated to the wound environment. When in contact with the wound bed, the dressing absorbs and retains bacteria within the matrix core of HydroClean® plus (Ousey et al, 2016). The dressing also sequesters and 'de-activates' factors that inhibit wound healing (e.g. excessive levels of proteinases) (Ousey et al, 2016b) (Box 1). The donation of fluid from the dressing and the simultaneous absorption of bacteria and tissue debris/proteinaceous material occurs as a result of the dressing's polyacrylate polymer affinity for the proteinaceous wound exudate. This mechanism results in the continuous rinsing and absorption effect seen with HydroClean® plus. Versions of HydroClean® plus are shown in Box 2.

HydroTac®

HydroTac® continues the beneficial absorption action of HydroClean® plus by absorbing wound exudate into the foam layer. The dressing maintains optimal hydration levels to support wound progression via AquaClear Technology, providing active moisture-release (Box 3) (Smola et al, 2014). In addition, the absorption properties of AquaClear Technology are designed to lead to the accumulation of growth factors within the moist wound environment. The combination of elevated growth factor levels and an optimally hydrated wound bed environment has been suggested to promote epithelial closure (Smola et al, 2016a,b). Versions of HydroTac® are shown in Box 4.

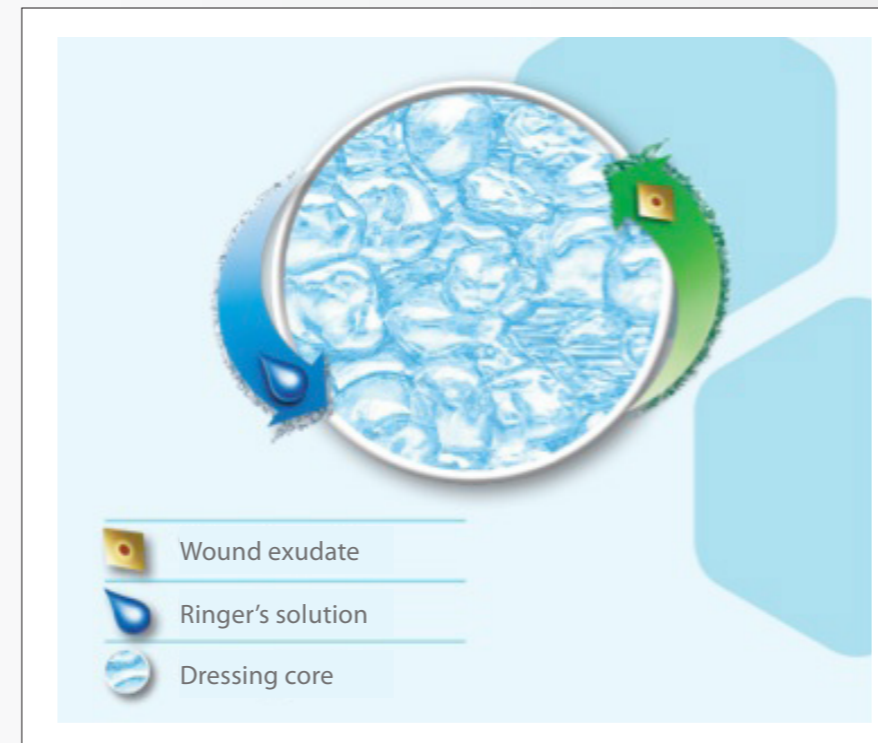

Figure 3. The unique cleansing/absorbing action of HydroClean® plus

WHAT IS THE EVIDENCE FOR USE?

The majority of acute and chronic wounds can be treated with HydroClean® plus and HydroTac®, including acute wounds (e.g. surgical wounds, skin tears), burns and chronic wounds (e.g. venous leg ulcers, pressure ulcers, diabetic foot ulcers, mixed aetiology ulcers) (Zollinger et al, 2014; Scherer et al, 2015; Ousey et al, 2016b; Smola et al, 2016a).

Laboratory studies have demonstrated that HydroClean plus is able to continuously deliver fluid to its surroundings whilst at the same time absorbing and binding proteins (Knestele, 2004). *In vitro* data have also showed that HydroClean plus absorbs and retains bacteria-laden wound exudate (Bruggisser, 2005). The sequestration and inactivation by SAP of proteinases found at elevated levels in chronic wound exudate, which are responsible for tissue breakdown, has also been shown (Eming et al, 2008). Laboratory-based experiments have shown that AquaClear Technology concentrates growth factors, leading to a stimulation of epithelial closure in a laboratory model system (Smola et al, 2016a).

Box 1: How HydroClean® plus works (Ousey et al, 2016b)

- A. The rinsing action of the continuous release of fluid (blue arrow) from the SAP core leads to softening of necrotic tissue and fibrin coatings (black) and uptake of bacteria- and protein-laden (black/red stars) wound exudate (red arrow).**
- B. The absorptive action continues the uptake of necrotic tissue, fibrinous material and exudate into the SAP core. These materials are retained within the core of the dressing.**
- C. The dressing action results in wound cleansing and the generation of an optimal wound environment for wound progression.**

Table 3. Evidence of HydroTherapy (Ousey et al, 2016b)		
Debridement and wound cleansing	In a 75-patient, observational, comparative study in patients with ulcers, the proportion of ulcer area covered by slough and necrosis reduced by 39.6% over a 2-week period In a 403-patient observational study in patients with a variety of ulcers, 56% of wounds were coated >50% with fibrin, which reduced to 8% within 1 month, while 32% of wounds coated with necrotic tissue reduced to 5% In a 20-patient, community-based study in patients with a variety of chronic wounds, there was a mean reduction of 62% in levels of devitalised tissue	Humbert et al, 2014; HARTMANN, 2010; Spruce et al, 2016
Bacterial sequestration	In a 221-patient observational study in patients with chronic wounds, there was a 44% reduction in clinical signs of infection In a 170-patient observational study in patients with chronic wounds, clinical signs of infection after 8 days were reduced from 24% to 17%	Kaspar et al, 2008; Kaspar, 2011
Management of wound exudate and periwound skin	In a 221-patient observational study in patients with chronic wounds, there was a reduction in the proportion of wounds with high exudate from 74% to 10%. Evaluation of the periwound skin reported reduction in erythema, maceration, eczema and hyperkeratosis In a 403-patient observational study in patients with a variety of ulcers, 75% of wounds were rated as having 'moderate' or 'severe' exudate levels. This level reduced to 4% after 1 month of treatment In a 20-patient study of chronic wounds, >50% of patients reported a reduction in wound exudate levels between initial and final assessment (mean 15 days) and there was an increase in percentage of patients with healthy periwound skin from 25% to 55% In a 270-patient observational study in patients with a variety of wounds, irritation of perilesional skin over an average of 9 days was reduced from 71% to 46%	Kaspar et al, 2008; HARTMANN, 2010; Spruce et al, 2016; Smola et al, 2016b
Granulation tissue formation	In a 75-patient, observational, comparative study in patients with ulcers, there was an absolute increase in the proportion of ulcer area covered by granulation tissue of 36%, compared with only 14.5% in the comparative group (hydrogel) In a 403-patient observational study in patients with a variety of ulcers, the proportion of wounds >50% filled with granulation tissue increased from 6% to 69% during the treatment period (average: 1 month) In a 42-patient RCT in chronic leg ulcers, there was a 26% increase in granulation tissue in the HRWD treatment group compared with an increase of only 10% in the comparative group (enzymatic preparation) over the course of 14 days' treatment In a 221-patient observational study in patients with chronic wounds, the number of wounds showing granulation tissue (>50% surface area) increased from 5% to 74% over the course of the 1-month treatment period	Humbert et al, 2014; HARTMANN, 2010; König et al, 2005; Kaspar et al, 2008
Epithelialisation	In 270-patient observational study in patients with a variety of hard-to-heal wounds where the wound bed consisted mostly of granulation tissue, the proportion of epithelial tissue over the course of the observation period (three dressing changes) increased from 16% to 28%	Smola et al, 2016b
Reduced pain	In a 37-patient observational study in patients with venous leg ulcers, 33 and 37 patients reported 'no pain' or 'slight pain' at dressing changes, respectively In a 221-patient study, patients reported a decrease in wound pain over the course of the 4-week treatment period, from 64% of patients experiencing 'intermediate' to 'high' pain perception, to 19% of patients In a 20-patient observational study in patients with chronic wounds, 95% of patients reported some degree of wound pain at the commencement of the observation period (mean 15 days) and this value reduced to 35%	Scholz et al, 1999; Kaspar et al, 2008; Spruce et al, 2016
Patient comfort	In a 403-patient observational study in patients with a variety of ulcers, >90% of patients rated the dressing 'good' or 'very good' on wearing and tolerability In a 20-patient community-based study, patients reported that the dressing was comfortable to wear at 99% of dressing changes and there were no reports of the dressing moving out of place from the wound	HARTMANN, 2010; Spruce et al, 2016