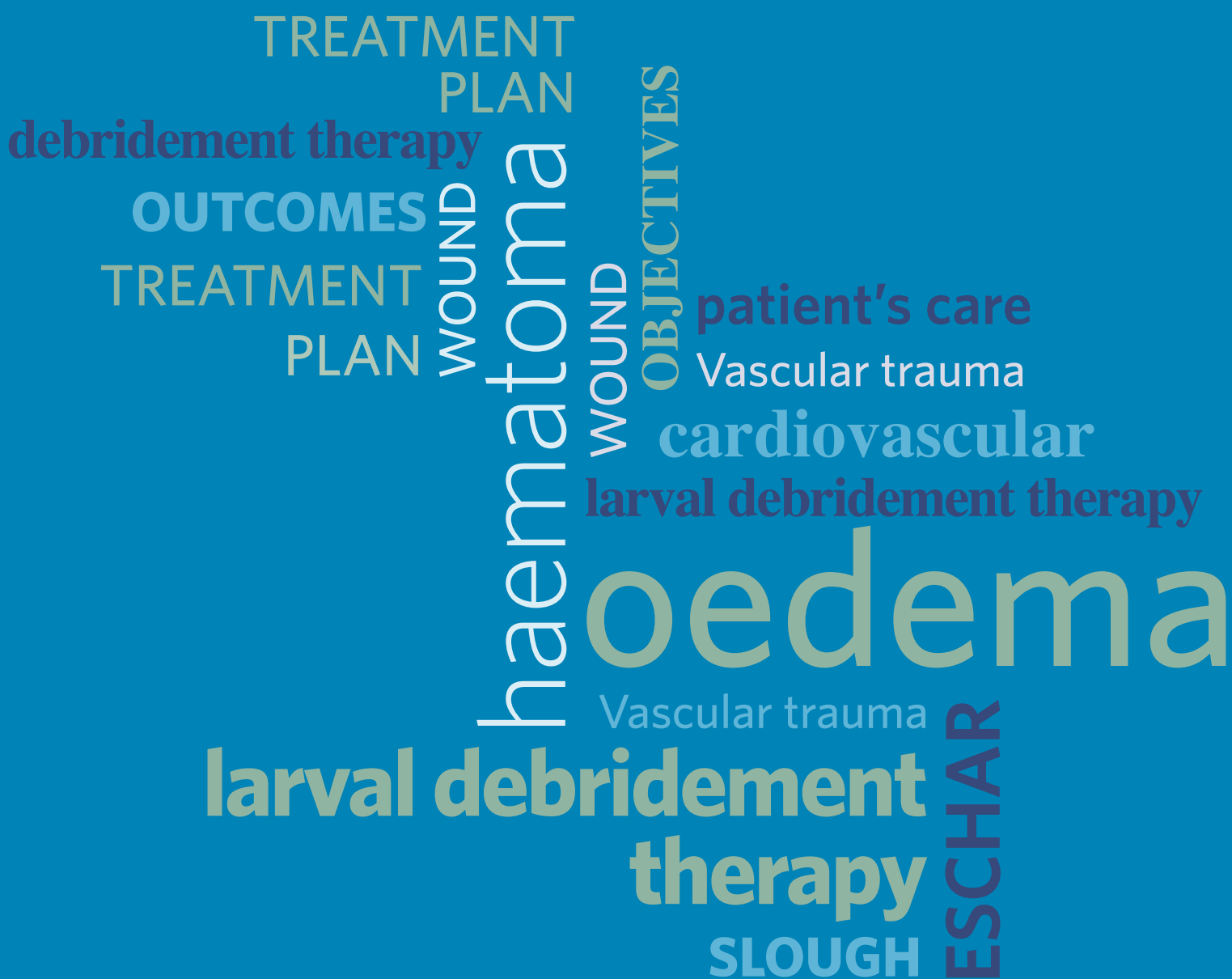

Larval debridement therapy: Traumatic injury management



FOREWORD

The last decade has seen considerable advances and improved survival from treating injured soldiers returning from the theatres of war in Iraq and Afghanistan and also in civilian practice following the developments of major trauma centres and networks in England.

Blast injury has generated catastrophic wounds, many to an extent not previously regarded as survivable, often with gross contamination and enormous reconstructive and wound management challenges. While topical negative pressure wound therapy has become the norm in managing these extensive wounds, there are many other areas of development that have led to improved wound management. Interestingly, the first prospective randomised clinical trial in wound management in a war zone has taken place in Camp Bastion, Afghanistan and that involved investigating the value of impregnated silver dressings in smaller wounds.

In England patients with life-threatening injuries, often with associated complex open fractures, are now predominantly managed in major trauma centres, providing ideal clinical environments for recruitment into clinical trials. While much progress has been made in wound management there is still much to be discovered and utilisation of our unique environment of battle wounds, and now the civilian cohorts, should be an opportunity that we should not miss.

Professor Sir Keith Porter

Professor of Clinical Traumatology, Clinical Service Lead for Trauma Services
Interim Chair of NIHR Surgical Reconstruction and Microbiology Research Centre, Queen Elizabeth Hospital Birmingham

PUBLISHED BY:

Wounds UK
Enterprise House
1-2 Hatfields
London SE1 9PG, UK
Tel: + 44 (0)20 7627 1510
Fax: +44 (0)20 7627 1570
www.wounds-uk.com

Wounds UK

© Wounds UK 2014



This document has been developed by Wounds UK and supported by BioMonde.

The views expressed are those of the authors and do not necessarily reflect those of BioMonde.

How to cite this document:

Geraghty J, Baisi L, Stephens C et al. *Larval debridement therapy: traumatic injury management*. London: Wounds UK, 2014 10(3). Supplement. Available to download from: www.wounds-uk.com

The role of larval debridement therapy in traumatic injuries

INTRODUCTION

Larval therapy use preceded World War I by hundreds of years but the first key milestone was the work of William S Baer, a military surgeon in 1917 who reported the successful use of larval therapy in the treatment of open fractures and abdominal wounds on the battlefields of France. He later applied his battlefield experiences to civilian patients, reporting successful wound closure and improved treatment of osteomyelitis (Baer, 1931).

The next milestone came with the development of commercially available larvae in the 1990s by Ronald Sherman and Edward Pechter. Despite huge technological advances in debridement techniques and the availability of antibiotics and other antimicrobial therapies, there is a continued role for using larval debridement therapy (LDT) in the management of traumatic injuries.

TRAUMATIC INJURIES

Traumatic injuries can be classified as penetrating, blunt or iatrogenic in aetiology. Vascular trauma, in particular, predominantly affects patients between 25 and 44 years old (80% of all injuries, mostly men) (National Centre for Injury and Prevention Control, 1995). Social and economic costs are significant, with a burden of 36 years of productive life lost (YPLL) for each traumatic death, compared with cancer (16 YPLL) and cardiovascular disease (12 YPLL) (Baker, 1992). The leading causes of injury include motor vehicle accidents, falls, fire-arm injuries, penetrating wounds and burns, all of which mainly affect the upper and lower limbs (over 80% of all cases) (Coimbra and Hoyt, 2010).

Traumatic wounds are complex and should incorporate a multidisciplinary approach including industry, medical and surgical teams, and wound specialists. LDT has been used effectively in wound care for a number of years (Thomas, 2006) as a method of debridement and has a number of advantages (Table 1).

| Table 1. Overview of evidence for larval debridement therapy | |
|--|--|
| The evidence base is growing and demonstrates the efficacy and safety of larval therapy for a variety of problematic wounds (Sherman, 2014). | |
| Advantages | Disadvantages |
| Established method (Sherman, 2014) | Not suitable for all wounds |
| Rapid but selective debridement (Gottrup and Jorgensen, 2011) | Slower than sharp or surgical debridement |
| Safe and effective alternative to sharp or surgical debridement in high-risk patients (Sherman, 2014) | Patients may not be concordant with therapy due to the 'yuck' factor |
| Secondary benefits may help to promote wound healing (Pritchard and Nigam, 2013) | May cause pain in ischaemic wounds (Mumcuoglu et al, 1999; Jones and Thomas, 2000) |
| May improve healing rates, reduce amputation rates and antibiotic use (Tian et al, 2013) | |
| Can be used in conjunction with NPWT (Brin et al, 2007) | |
| No reported toxicity or allergenicity (Vowden and Vowden, 2002) | |
| May decrease overall treatment costs (Bennett et al, 2013) | |

"A recent economic evaluation comparing available debridement interventions found larval therapy to be more cost-effective than comparator debridement therapies"

BASIC RATIONALE FOR LARVAL DEBRIDEMENT THERAPY

The primary action of LDT is to debride the wound (Pritchard and Nigam, 2013). Larvae of the greenbottle fly *Lucilia sericata* are used to remove slough and dead or devitalised tissue from the wound bed, leaving healthy granulation tissue (Telford et al, 2010). There is also some evidence to suggest that deep tissue debridement is possible, which may lead to more rapid removal of debris compared to many other non-surgical treatments (Sherman, 2014).

Recent research and publication of more evidence has brought to light how larvae selectively remove devitalised tissue and promote other activities that contribute to wound healing (Nigam, 2013; Pritchard and Nigam, 2013; Sherman, 2014). Laboratory studies have shown that larval secretions/excretions contain antimicrobial substances that kill microorganisms, and contain chemicals that promote tissue regeneration and restore normal wound healing processes (Cazander et al, 2013; Nigam 2013; Sherman, 2014).

A recent economic evaluation comparing available debridement interventions found larval therapy to be more cost-effective than comparator debridement therapies, including surgical, sharp, mechanical and autolytic debridement (Bennett et al, 2013). Larval therapy can be performed easily and quickly by any qualified healthcare professional with appropriate training and support, and is a key tool for the management of complex trauma wounds.

REFERENCES

- Baer WS. The treatment of chronic osteomyelitis with the maggot (larvae of the blowfly). *J Bone Joint Surg* 1931;13: 438-74
- Baker S (1992) *The Injury Fact Book*. New York: Oxford University Press.
- Bennett H, Sewell B, Anderson P et al (2013) Cost-effectiveness of interventions for chronic wound debridement: an evaluation in search of data. *Wounds UK* 9(4 Suppl): 3-11
- Brin YS, Mumcuoglu KY, Massarwe S et al (2007) Chronic foot ulcer management using maggot debridement and topical negative pressure therapy. *J Wound Care* 16(3): 111-3
- Cazander G, van der Veerdonk MC, Vandenbrouke-Grauls CM et al (2010) Maggot excretions inhibit biofilm formation on biomaterials. *Clin Orthop Relat Res* 468(10): 2789-96
- Coimbra R, Hoyt D (2010) Vascular trauma: Epidemiology and natural history. In: *Rutherford Vascular Surgery* (7th edn). Philadelphia: Elsevier Saunders
- Gottrup F, Jorgensen B (2011) Maggot debridement: An alternative method for debridement. *J Plastic Surg* 11: 290-302
- Jones M, Thomas S (2000) Larval therapy. *Nurs Stand* 14(20):47-51
- Mumcuoglu K, Ingber A, Gilead L et al. (1999) Maggot therapy for the treatment of intractable wounds. *Int J Dermatol* 38: 623-7
- National Centre for Injury and Prevention (1995) *Overall injury and adverse-event-related deaths and rate per 100,000, E800-E999*. Retrieved online from: National Centre for Injury and Prevention Control, Centres for Disease Control and Prevention
- Nigam Y (2013) Evidence for larval debridement therapy in wound cleansing and healing. *Wounds UK* 9(4 Suppl): 12-6
- Pritchard DI, Nigam Y (2013) Maximising the secondary beneficial effects of larval debridement therapy. *J Wound Care* 22(11): 610-6
- Sherman RA (2014) Mechanisms of maggot induced wound healing: What do we know, and where do we go from here? *Evid Based Complement Alternat Med* 592419. Epub
- Telford G, Brown AP, Seabra RA et al (2010) Degradation of eschar from venous leg ulcers using a recombinant chymotrypsin from *Lucilia sericata*. *Br J Dermatol* 163(3): 523-31
- Tian X, Liang XM, Song GM et al (2013) Maggot debridement therapy for the treatment of diabetic foot ulcers: a meta-analysis. *J Wound Care* 22(9): 462-9
- Thomas S, Jones M, Wynn K, Fowler T. The current status of larval therapy in wound healing. *Br J Nurs* 2001; 10(22): S5-12
- Vowden K, Vowden P (2002) Wound bed preparation. *World Wide Wounds*. Available from: <http://www.worldwidewounds.com/2002/april/Vowden/Wound-Bed-Preparation.html>
- Wounds UK (2013) *Effective debridement in a changing NHS: A UK consensus*. Wounds UK. Available at: www.wounds-uk.com

The use of larval debridement therapy in traumatic haematoma wounds

Authors:

Jemell Geraghty, Lead Nurse,
Tissue Viability, Royal Free
London NHS Foundation
Trust, London

Lukla Biasi, Senior Clinical
Fellow, Vascular Department,
Guy's and St. Thomas' NHS
Foundation Trust, London

Haematomas are normally caused by a traumatic injury as a result of blunt force or trauma. They typically occur on the lower limbs as a result of pretibial shearing which can cause separation of the skin and the subcutaneous tissue from the muscle fascia (Pagan and Hunter, 2011).

There are varying degrees of anatomical bleeding in regards to the skin and mucosa. *Purpura* is defined as a collection of blood greater than 3mm in diameter into the surface of the skin. *Petechiae* are pinpoint, flat, round red spots under the skin surface (derma) caused by intradermal haemorrhage due to red blood cell extravasation from capillaries; *petechiae* are less than 3mm in diameter. *Ecchymosis* is a more extensive, yet non-raised, subcutaneous bleeding from ruptured arterioles and venules. Finally, a *haematoma* is classified and distinguished as a deeper, palpable collection of blood (Handin, 2011).

Due to complex care needs, the elderly adult population is, to some extent, inherently vulnerable to traumas — such as falls, bedside injuries and fractures — that have the potential for haematoma formation (Beldon, 2011). Assessment and treatment of lower limb haematomas are further complicated by ageing skin and various co-morbidities associated with this group of patients, such as reduced mobility or bed-bound status, general frailty/unsuitability for surgical intervention, risk of infection, pain management and overall wellbeing.

IMPORTANCE OF ACCURATE ASSESSMENT

A thorough, holistic assessment by medical/surgical, nursing and tissue viability teams must be based on the current medical and psychological state of the patient, and the risk of surgical intervention or conservative management must be weighed against the possible complications. The main challenge is in identifying the underlying cause and pathophysiology of the haematoma/bleeding.

Untreated vascular lesions may result in acute ischaemia, compartment syndrome and or pseudoaneurysm. If the acute onset of symptoms is detected within six hours, the chance of limb salvage is 90% — however, if undetected for longer than 24 hours, the chance falls dramatically, to 20% (Weaver et al, 1984). Primary amputation may be considered when the patient is haemodynamically unstable and/or the neurological deficit of the limb is irreversible.

Arterial injury is the most threatening underlying aetiology of soft-tissue haematomas. Knowledge of the clinical presentation and natural history of vascular trauma (blunt trauma, high-velocity/low-velocity penetrating trauma) is important when dealing with haematomas at the extremities. Haematoma in this setting is the result of blood extravasation in the soft tissues and the potential epiphenomenon of a more urgent clinical scenario requiring immediate surgical exploration. It is important to note that, in cases where patients are admitted to hospital under a specific team such as cardiology or respiratory, it may be necessary to refer them to the relevant vascular or plastic surgery specialist for an opinion.

As in the case study (see pp 4-5), it is advised that all patients with a lower-limb haematoma have at minimum a diagnostic recording of the ankle brachial pressure index to establish a vascular baseline. In addition, a marker of international normalised ratio (INR) measurement should be taken to assess how long it takes an individual's blood to clot compared to the average. After these steps, the proposed therapy should be discussed with the patient and consent gained and documented in the relevant nursing and medical notes.

CHOOSING A COURSE OF ACTION

The traditional care pathway for management of a large haematoma would be surgical debridement performed in theatre. However, over the past decade, the use of larval

debridement therapy (LDT) has become an acceptable method for debriding traumatic haematomas of the lower limb, as its use may prevent further surgical intervention, reduce hospital stay and improve patient outcomes in regards to pain and anxiety.

As with any therapy, safety and optimising effectiveness must be considered in line with the extent of the haematoma and the overall clinical requirements of the patient. Before commencing LDT, a number of key issues should be discussed with the multidisciplinary team and the patient. Firstly the size, position, depth, severity, duration of bleeding and clinical setting or patient state must be assessed. Muco-cutaneous bleeding suggests a platelet disorder. Bleeding into potential spaces (joints, fascial planes, and retroperitoneum) suggests a coagulation factor deficiency. Spontaneous soft tissue haematoma or extensive bruising in previously asymptomatic patients might suggest accidental warfarin ingestion or a disorder of the haemostatic process (e.g. acquired factor V, VIII, vWF inhibitors) and causes of prolonged partial thromboplastin time or activated partial thromboplastin time must be investigated. Postoperative bleeding at a surgical site is usually related to a local surgical problem that needs to be promptly addressed by a surgeon (Baz and Mekhail, 2013).

It is important that patients, families and nursing staff understand the protocol, duration and management of LDT in treating haematomas. Full explanation and documentation is key to ensuring the foundation of care is put in place. The most common presentation of extremity artery injury is acute ischaemia and, very rarely, external bleeding; the presence of a pulsatile haematoma (pseudonaerysm) or compartment syndrome is very suggestive of an arterial lesion of a major vessel, and these contraindications of LDT must be kept in mind when deciding on the treatment plan (Coimbra et al, 2010).

DEBRIDEMENT OF HAEMATOMAS

Removal of devitalised or non-viable tissue from the wound bed is essential to prepare the wound bed and facilitate angiogenesis (Leaper et al, 2012). The decision to perform LDT in the case of haematoma treatment must be made by a multidisciplinary team that includes relevant medical

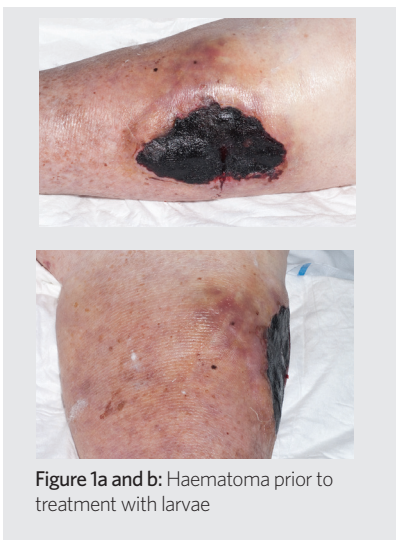


Figure 1a and b: Haematoma prior to treatment with larvae

CASE STUDY: HAEMATOMA OF THE LOWER LEG

Ms W, an 87-year-old female, presented with a traumatic haematoma to the lower limb after a fall at home (Figure 1a and b). She had a history of bilateral knee replacements; BMI of 29, indicating she was overweight for her height; and chronic obstructive pulmonary disease, which made her a poor candidate for surgical intervention with general anaesthesia. She lived at home alone with care input four times a day.

ASSESSMENT

Although haematomas are not truly necrotic, they do present with non-viable tissue that needs to be removed from the wound bed to enable healing (Rafter, 2012). Traditional methods of haematoma excision and debridement were not considered appropriate because the patient was already in respiratory distress, and spent most of the day bed- or chair-bound due to her increased immobility and corresponding weight challenges. The multidisciplinary team wanted to treat the wound non-invasively, aiming to minimise the patient's stay in hospital, and to avoid surgery and potential complications in terms of mobility, respiration and infection.

After successful Doppler and vascular assessment, including duplex scanning, her ankle-brachial pressure index was determined as 0.8 for both legs. This assessment is always carried out by the

and surgical teams, and specialist nurses involved with the patient's care. The application of larval therapy may be performed by any qualified healthcare practitioner who has reached an appropriate level of competency through training and who has adequate provision of clinical support (AWTVN, 2013).

Clinical studies, not specific to haematomas and mainly related to chronic ulcer treatment, have reported improved rates of limb salvage when using LDT (Gottrup and Jorgensen, 2011) and faster healing rates (Tian et al, 2013). Single case reports have shown the feasibility of LDT in the treatment of haematomas. In a recent single case study, LDT was used to debride two haematomas in a patient not suitable for theatre due to her comorbidities. There was effective debridement within a 9-week period and the patient was able to go home and be treated as an outpatient by the district nursing team (Rafter, 2012). A further case is outlined below. However, further RCTs should be specifically designed to reach level A evidence (www.cebm.net) on the efficacy of LDT (Wood and Hughes, 2013).

LARVAL DEBRIDEMENT THERAPY IN PRACTICE

In general, the application of LDT is similar in haematoma treatment to that for other wounds. The use of the BioBag is typically favoured over free-range application; however, choice of application depends on the individual patient and the extent of the haematoma. When using the BioBag, the outer dressing may require more frequent changing due to the likelihood of excessive exudate, and use of a secondary deodorising dressing (e.g. activated charcoal) is advised to address malodour problems, which are common with haematomas being treated with larvae.

When applying LDT to the lower limb in treating a traumatic haematoma, the leg should be bandaged using a soft protective bandage and secured with crepe, applied lightly from toe to knee. Doing so will keep the therapy in place, aid patient comfort and help reduce surrounding oedema. Good skin care of the surrounding area is also important for reducing inflammatory skin changes, discomfort or itch in line with general washing of the limb. Pain levels should be monitored regularly, as with any treatment, and care decisions related to pain based on individual requirements.

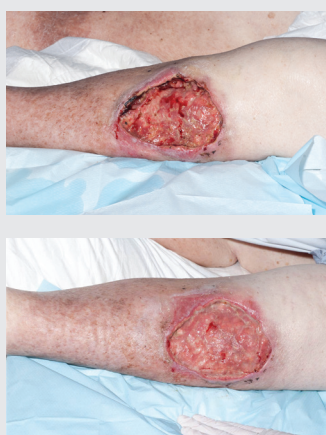

Figure 2a and b: Debridement of haematoma following treatment with larvae

tissue viability team on all wounds to the legs and forms the foundation of assessment. It was decided that larval debridement therapy (LDT) applied using the BioBag would be initiated, as both patient and staff had reservations about using free-range larvae due to the so-called 'yuck' factor.

TREATMENT

On initial application, two small incisions were made in the haematoma, and the BioBag was placed over the haematoma. The surrounding skin was protected with a hydrocolloid dressing. The leg was then bandaged from toe to knee conservatively with Softban dressing and crepe. Gentle ankle and calf exercises were recommended throughout the treatment along with leg elevation as tolerated. In total, there were three applications of LDT following this protocol.

OUTCOME

After one application, there was a dramatic reduction in non-viable tissue. The subsequent treatments were used to fully debride the wound and encourage granulation (Figure 2a and b). Following treatment, the patient had been transferred to a rehabilitation unit (to aid her mobility), where the local tissue viability nurse was able to dress the wound conservatively.

"Larval therapy has been shown to be an effective form of debridement in the full excision and removal of a traumatic haematoma"

Results with LDT in managing haematoma of the lower extremities are usually immediate with the first application. However, a further application may be required depending on the extent of the injury. It is useful to photograph the haematoma before and after with the patient's consent to illustrate the impact of the intervention and to liaise with the medical team to ensure treatment continues for as long as required.

Once successful debridement has taken place, the wound will require further assessment to determine treatment with options such as topical negative pressure wound therapy and conservative secondary dressings. Using this approach, further surgical intervention may be avoided and patients can be discharged back home, to be followed by the primary care team.

MAKING THE CASE FOR LDT IN HAEMATOMAS

More often than not, invasive forms of surgical debridement are used to treat traumatic haematomas in the older population. This method can be seen as a quick answer in terms of surgery; however, the implications for the patient can be significant in terms of length of hospital stay, pain and possible further wound complications. In addition, there are costs in terms of long-term dressings and nursing time in both the acute and community settings. LDT may provide a cost-effective alternative with the potential to reduce overall treatment costs (Bennett et al, 2013).

If a therapy has the potential to work the same as or better than conventional treatment, it should be considered as first line in the treatment of traumatic haematomas. LDT has been shown to be an effective form of debridement in the full excision and removal of a traumatic haematoma. Formal first line consensus and treatment of haematomas using LDT is currently being explored within our trust, and should be more widely explored to ensure optimisation of this valuable resource.

REFERENCES

- All Wales Tissue Viability Nurse Forum (AWTVN) (2013) *All Wales Guidance for the use of Larval Debridement Therapy*. AWTVN. Available from www.wounds-uk.com
- Baz R, Mekhail T (2013) *Bleeding Disorders*. Cleveland Clinic, Center for Continuing Education. Available at: www.clevelandclinicmeded.com/medicalpubs/diseasemanagement/hematology-oncology/bleeding-disorders
- Beldon P (2011) Haematoma: Assessment, treatment and management. *Wound Essentials* 6(1):36-9. Available at: <http://www.wounds-uk.com/wound-essentials/wound-essentials-6-haematoma-assessment-treatment-and-management>
- Bennett H, Sewell B, Anderson P et al (2013) Cost-effectiveness of interventions for chronic wound debridement: an evaluation in search of data. *Wounds UK* 9(4 Suppl): 3-11
- Coimbra R, Hoyt D (2010) Vascular trauma: Epidemiology and natural history. In: *Rutherford Vascular Surgery* (7th edn). Philadelphia: Elsevier Saunders
- Gottrup F, Jorgensen B (2011) Maggot debridement: An alternative method of debridement. *J Plastic Surg* 11: 290-302
- Handin RI (2011) Hemorrhage and thrombosis. In: *Harrison's Principles of Internal Medicine*. (18th edn). London: McGraw-Hill
- Leaper D, Schultz G, Carville K, et al (2012) *Extending the TIME concept: what have we learned in the past 10 years?* *Int Wound J* 9 (Suppl 2): 1-19
- Pagan M, Hunter J (2011) Lower leg haematomas: Potential for complications in older people. *Wound Practice Res* 19(1):21-8
- Rafter L (2012) Debridement of a traumatic haematoma using larval therapy. *Wounds UK* 8(1):81-8
- Tian X, Liang XM, Song GM, et al (2013) Maggot debridement therapy for the treatment of diabetic foot ulcers: a meta-analysis. *J Wound Care* 22(9): 462-9
- Weaver FA, Rosenthal RE, Waterhouse G, Adkins RB (1984) Combined skeletal and vascular injuries of the lower extremities. *American Surgery* 50(4): 189-97
- Wood L, Hughes M (2013) Reviewing the effectiveness of larval therapy. *J Community Nurs* 27(2): 11-14

Larval debridement therapy as a management option in complex traumatic wounds

Authors:

Claire Stephens, Specialist Nurse, Welsh Wound Innovation Centre, Cardiff, Wales

Prof Lt Col Steve Jeffrey, Consultant Plastic Surgeon, The Queen Elizabeth Hospital, Birmingham, UK

Lesley Street, Burns and Plastics Specialist Nurse, Queen Elizabeth Hospital Birmingham

Wounds can generally be defined broadly as acute, chronic, surgical and traumatic wounds, but there is not yet a clear definition of 'complex wounds' or specific criteria to separate them from simpler ones (Ferreira, 2006). Wounds described with the term 'complex' will involve one or more underlying comorbid or complicating factors that hinder wound healing progress or closure. A complex wound arising from traumatic insult or injury will often be associated with specific related complicating factors rather than comorbidities alone and, as such, will require a unique multifactorial approach to facilitate tissue salvage, wound closure and rehabilitation.

UNDERSTANDING COMPLEX TRAUMATIC WOUNDS

Traumatic injury — whether penetrating, puncture, crush or thermal in origin — may result in excessive blood, tissue, muscle or bone loss; damage to or loss of underlying structures; and complications due to severe contamination at the point of injury. Exposed wound surface areas are vulnerable to biofilm formation and infection, and may result in wound stasis or recurrent wound breakdown. These wounds therefore require multiple repeated episodes of wound bed debridement and management of biofilm or wound infection to prevent secondary complications such as progression of soft-tissue loss or osteomyelitis.

DEBRIDEMENT IN COMPLEX TRAUMATIC WOUNDS

The presence of necrotic tissue can delay wound healing. Necrotic tissue lacks the ability to fight against microbes, instead providing them the nutrients and conditions to allow rapid multiplication and subsequent invasion to adjacent viable tissue.

There are two ways to mitigate this. First, the presence of the necrotic tissue can be accepted, and microbial growth within the necrotic tissue can be suppressed with the use of an antimicrobial agent. This suppression will depend on the ability of the antimicrobial agent to penetrate the tissues, with most antimicrobial agents only able to penetrate to a limited extent. This approach is therefore most commonly used where the necrotic layer is very thin such as in a superficial to mid-depth burn where microbial growth in the slough will often be managed by saturating the slough with (for example) a silver dressing (Jeffery, 2010).

Secondly, the necrotic tissue can be removed (debrided) by a range of methods, including surgical/sharp, mechanical, hydrosurgical, biosurgical (larval) and ultrasonic. However, not all of these methods are appropriate for use in complex trauma wounds, nor may they be the most cost-effective. Larval debridement therapy (LDT) fits both these criteria and should be considered in the management of complex traumatic wounds to optimise the management of these often critically ill patients (Box 1).

MAKING THE CASE FOR LDT IN COMPLEX TRAUMA WOUNDS

Importantly, LDT can be performed without the use of anaesthesia. People are living longer, and chronic comorbidities (e.g. diabetes, obesity) are increasing in the population as a whole. The more comorbidities a patient has, the greater the risk posed by undergoing a procedure with general anaesthesia. Thus the surgeon is faced with a dilemma when considering how to debride a trauma

Box 1: Using larval therapy in complex traumatic wounds

- Provides debridement/wound bed preparation before surgical closure
- Can help prevent osteomyelitis and amputation (Buchman and Blair, 1932)
- Can be combined with surgical debridement techniques for maintenance debridement (Wounds UK, 2013)
- Prior to use, remove any visible residues of topical treatments (e.g. hydrogels) by cleansing or irrigating the wound bed
- Cannot be used on exposed organs and major blood vessels

wound — especially if the risk of anaesthesia is too great. Other patients may be reluctant or refuse to have surgery. In these patients, LDT can be applied to remove the necrotic tissue without the associated risks of general anaesthesia.

Furthermore, LDT is highly selective; the larvae debride only the necrotic tissue and leave behind living, healthy tissue (Telford et al, 2010). Most other debridement techniques will typically remove a margin of healthy tissue along with the necrotic tissue. Trauma patients in particular cannot afford to lose any healthy tissue — LDT helps preserve this crucial tissue.

Although this method will not be appropriate for all patients, it should be an option in elderly and younger trauma patients alike — particularly as preservation of the limb, efficacious healing and quality of life after treatment will be of the utmost importance to younger patient.

REFERENCES

- Buchman J, Blair JE. Maggots and their use in the treatment of chronic osteomyelitis. *Surg Gynecol Obstet* 1932; 55:177-90
- Ferreira MC, Tuma P Jr, Carvalho VF, Kamamoto F (2006) Complex wounds. *Clinics (Sao Paulo)* 61(6): 571-8
- Jeffery SLA. *The Management of Burns*. Oxford Desk Reference: Major Trauma, Oxford University Press 2010. ISBN 978-0199543328
- Telford G, Brown AP, Seabra RA et al (2010) Degradation of eschar from venous leg ulcers using a recombinant chymotrypsin from *Lucilia sericata*. *Br J Dermatol* 163(3): 523-31
- Wounds UK (2013) *Effective debridement in a changing NHS. A consensus document*. Wounds UK. Available from: www.wounds-uk.com

CASE STUDY: COMPLEX TRAUMATIC INJURIES SUSTAINED IN VEHICLE EXPLOSION

Mr C, a 47-year-old male, sustained traumatic chest, thermal and penetrating injuries in a vehicle collision and subsequent vehicle explosion. The patient was very unstable upon arrival to hospital, having sustained crushing chest injuries that prevented his undergoing surgical debridement in theatre.

Due to the vast surface area of the arm injury and devitalised tissue present, the patient was showing early signs of sepsis. In order to achieve debridement and wound bed preparation, prevent infection, minimise pain, avoid surgery and maximise healthy tissue preservation, the decision was made to initiate larval debridement therapy (LDT) (Figure 1).

Larvae were applied to the wound using BioBags for 4 days (Figure 2). These were easy to apply and the larvae and we were able to target the burn. The Biobags were held in place with damp gauze and a loose bandage to allow observation of the larvae 48 hours post-application. Prior to starting treatment, the patient had begun moving into a septic episode. However, all clinical signs of infection were reduced after 24 hours. At the end of the treatment period, devitalised tissue had been reduced by the larvae and the wound bed contained much cleaner tissue (Figures 3 and 4). The patient was taken for skin grafting as soon as he was stable to support his rehabilitation.

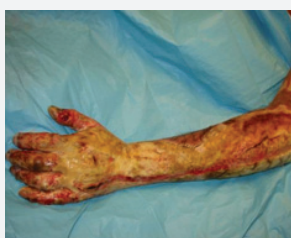

Figure 1: Before larvae

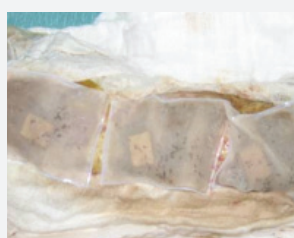

Figure 2: Larvae *in situ*

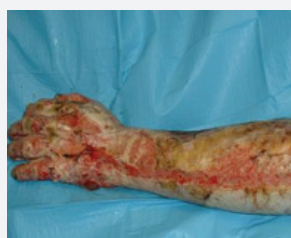

Figure 3: Three days post-larvae

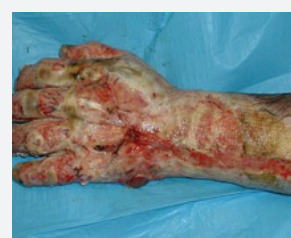

Figure 4: Close-up of hand 4 days post-larvae

Use of larval debridement therapy in burns where surgery is contraindicated

Claire Hayward, Clinical Nurse Specialist, Burns Outreach, Queen Victoria Hospital NHS Foundation Trust, East Grinstead, UK

Grafting and surgical debridement remain the gold standard of burn care. However, not all patients are suitable for these treatments. Although burn care continues to improve, thus increasing healing rates and enhancing patient quality of life, challenges remain, particularly in elderly patients and those with complex comorbid conditions. When burns occur in these types of patients, a second trauma to create a donor site wound may impede overall recovery, or the donor site may become a chronic wound. In addition, grafting requires that patients undergo surgery, but high-risk patients often are not suitable for anaesthesia. Many elderly patients are also averse to undergoing surgery and wish to avoid it if possible. None of these factors changes that, in order to accelerate healing in wounds, debridement is required.

TRADITIONAL TREATMENTS OF FULL-THICKNESS BURNS

Tangential excision is a surgical treatment that requires repeated visits and procedures. The clinical and patient time required can be extensive, which can be a drain on clinic resources, patients and carers. In addition, it is important in burn patients in general and in more complicated patients in particular to preserve as much healthy granulation tissue as possible. Particularly in high-risk patients, tangential excision can result in the loss of some tissue that is important for epithelialisation and efficacious healing, which can lead to slow deterioration of the wound and increased risk of infection (Baux et al, 1989).

Local protocol for deep dermal and full-thickness burns that are not appropriate for surgical debridement and repair calls for application of Flammeccerium, an antimicrobial cream that controls bacterial load and stabilises the wound (Edwards, 2006). It also lays down a pseudo-eschar that helps protect the wound against infection. This treatment is effective for preventing infection, but does not aid debridement, and the burn eschar often takes a long time to separate.

Full-thickness burns heal only by contraction from the wound edges and exhibit limited re-epithelialisation. However, when large burns are not debrided, there is a risk they might not heal, and those that do heal take an extended time and result in extensive scarring. Very few burns are strictly full-thickness; most are mixed-depth, with some deep areas and some remaining dermis. These wounds maintain the ability to granulate and re-epithelialise. To accelerate the debridement process in these wounds, larval debridement therapy (LDT) has been shown in certain cases to be effective (Akhtar et al, 2011; Namias et al, 2000).

RATIONALE FOR LARVAL DEBRIDEMENT THERAPY IN BURNS

Where surgical debridement is not an option and rapid removal of devitalised tissue is required, larval therapy is a recognised option (Boulton, 2007). Larval therapy can be used on a variety of wounds, including leg ulcers, pressure ulcers, traumatic wounds, burns, infected wounds, wounds containing meticillin-resistant *Staphylococcus aureus* and amputation sites (Baker

Box 1: Benefits of the use of larval debridement therapy

- Rapid/selective debridement (Boulton 2007; Sherman, 2014)
- Do not ingest healthy, living tissue (Telford et al, 2010)
- Antimicrobial effect within the wound (Cazander et al, 2013; Nigam, 2013; Sherman, 2014)
- Deodorisation of the wound (Nigam, 2013)
- Stimulation of production of granulation tissue (Nigam, 2013; Sherman, 2014)

et al, 2010). A burn wound that has some functional dermis remaining benefits — like any other wound — from the use of larvae, or biosurgical debridement (Box 1). Furthermore, for patients not suitable for surgical intervention, larval debridement presents a means by which to accelerate burn healing.

FACTORS TO CONSIDER BEFORE AND DURING USE

LDT has been used mainly used by the outreach service on burn wounds that are a few weeks old and starting to show signs of healing. In addition to holistic assessment of the patient's condition and history, the wound is assessed for depth and tissue types.

Larval debridement is appropriate in partial-thickness burns where there is poor healing and underlying factors that make a patient high-risk for infection. This method has, in our experience, been found to speed healing and prevent the development of infection. Mixed-depth burns that have some sloughy, yellow, soft tissue — on the surface, under the necrotic tissue (so the eschar is beginning to lift) or at the edges — are appropriate for LDT (Akhtar et al, 2011). This is the type of tissue that the larvae will selectively debride by breaking down, removing the devitalised tissue to allow new, healthy tissue to grow (Telford et al, 2010; Pritchard and Nigam, 2013). At least one case study in the literature has used LDT on fourth-degree burns, with damage to sub-dermal tissue, but this has not been done in our practice (Namias et al, 2000).

Burns of any size can benefit from LDT. On large wounds, bagged larvae can be used to allow ongoing visual assessment of the wound; they can be repositioned, if needed, to the areas of slough. Where there is hard eschar and the beginnings of lifting around the edges of the burn, free-range larvae work well, as they can burrow in at these points and debride under the unhealthy tissue.

CASE STUDY: LARVAL DEBRIDEMENT IN A BURN WOUND

To examine whether LDT is an effective method of debriding burn wounds in patients who are unable to undergo surgery, three case studies were undertaken and documented. In the one presented here, the patient is an 80-year-old with a mixed-depth burn to the abdomen and left thigh. The burn occurred after the patient had collapsed next to a heater. The wound was initially treated with Flammercerium. It presented with high levels of exudate and was very malodorous.

Five weeks post-injury, larvae were applied to the wound in the BioBag. LDT was used for 5 days, and the bag was moved to a new location each day due to the awkward shape of the wound, to ensure full debridement (Figure 1).

OUTCOME

After just one treatment with LDT, odour had resolved, and exudate levels had reduced. The patient did not complain of discomfort or report any adverse affects. The district nurses who provided treatment in conjunction with the outreach unit found the treatment very straightforward to administer; directing them in the steps involved was simple, and LDT was carried out with no issues or miscommunications. After LDT, advanced wound dressings were not needed. Because debridement had been achieved, a simple non-adherent dressing was applied, with dressing changes twice weekly, and the patient went on to healing 4 weeks later (Figures 2 and 3).

"We have found that patients prefer the larvae in bags. Physical discomfort has not been an issue for patients in our experience."

In the case of full-thickness burns with thick, hard eschar, LDT is not indicated. The larvae cannot penetrate this type of tissue and, therefore, have no effect on wound healing. For these patients, it is recommended to wait for some autolytic debridement to take place, at which time LDT can be implemented (Jones, 2009). Larvae also should not be applied to wounds that have a tendency to bleed easily, or be introduced into wounds that communicate with a body cavity or internal organ (Acton, 2007). Particularly in burn wounds, location is a consideration: if used on areas such as the buttocks, lower back or soles of the feet, areas of direct pressure should be alleviated as the larvae may be compromised (Thornton, 2002).

Because larvae are living organisms, they can be affected by compounds in dressings and topical substances. For example, the propylene-glycol used in many hydrogel dressings is toxic to larvae, so wounds must be thoroughly irrigated if these dressings have been used (Challinor, 2012). Flammercerium can be similarly toxic to larvae, so thorough irrigation and cleansing to remove visible residues should be performed.

Achievement of patient concordance with LDT tends to be the same in patients with burns as those with other wounds (e.g. psychological acceptance, the 'yuck' factor). We have found that patients prefer the larvae in bags. Physical discomfort has not been an issue for patients in our experience.

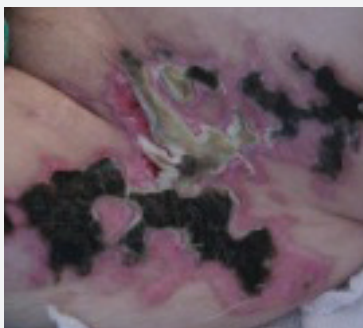

Figure 1. 5 weeks post-injury

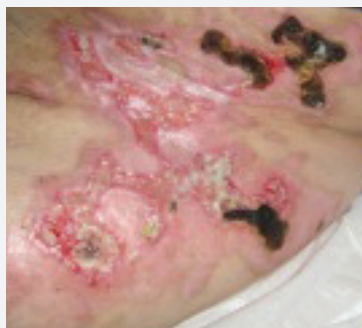

Figure 2. 6 weeks post-injury

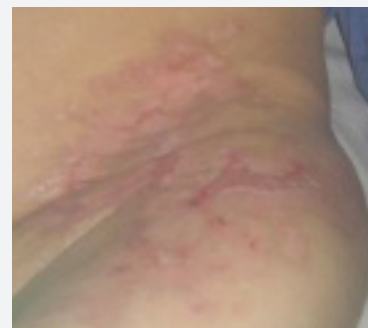

Figure 3. 10 weeks post-injury

MAKING THE CASE FOR LDT IN BURNS

Although LDT has a long history of use in wound care, the literature suggests LDT is not frequently used in the treatment and management of burn wounds. The evidence around LDT does not contraindicate its use in burns and, in fact, provides the same benefits in burns that are difficult to heal and in patients for whom surgery is not an option.

LDT is an inexpensive, quick mode of burn wound debridement that can be carried out on an in- or outpatient basis (Edwards, 2006). It has been used by our service to manage burns in a wide range of cases. The effectiveness of LDT for debriding slough, eliminating thick eschar, preventing infection and controlling exudate levels and malodour has been demonstrated in clinical practice.

REFERENCES

- Acton C (2007) A know-how guide to using larval therapy for wound debridement. *Wound Essentials* 2: 156–9. Available at: www.wounds-uk.com/wound-essentials/wound-essentials-2-a-know-how-guide-to-using-larval-therapy-for-wound-debridement
- Akhtar N, Abdel-Rehim S, Rodrigues J, Brooks P (2011) The use of larvae therapy to debride full thickness burns in the anaesthetically unfit patient: The Nottingham experience. *Burns* 37(6): e44–9
- All Wales Tissue Viability Nurse Forum (2013) *All Wales guidance for the use of larval debridement therapy*. London: Wounds UK. Available at: www.wounds-uk.com/supplements/awtvnf-larval-debridement-therapy
- Baker A, Craven, Cameron M, et al (2010) *Guidelines for the use of sterile maggot therapy in wound management*. Derby City, Primary Care Trust
- Baux S, Mimoun M, Saade H, et al (1989) Burns in the elderly. *Burns* 15(4): 239–40
- Benbow M (2005) *Evidence-based wound management*. Whurr Publishers, London
- Boulton A (2007) Maggots rid patients of MRSA, Press release. Available online at: www.medicine.manchester.ac.uk/aboutus/news/mrsamaggots
- Challinor T (2012) Uncovering the evidence on larval therapy. *Wound Essentials* 7(1): 102–6. Available at: www.wounds-uk.com/wound-essentials/wound-essentials-71-uncovering-the-evidence-on-larval-therapy
- Edwards J (2006) Larval therapy in full thickness burns. *J Community Nurs* 20(10):33–8. Available at: www.jcn.co.uk/journal/10-2006/wound-management/969-larval-therapy-in-full-thickness-burns/
- Jones M (2009) An overview of maggot therapy used on chronic wounds in the community. *Br J Comm Nurs* 14(3 Suppl): S16–S20
- Ferreira MC, Tuma P Jr, Carvalho VF, Kamamoto F (2006) Complex wounds. *Clinics (Sao Paulo)* 61(6): 571–8
- Namias N, Varela JE, Varas RP, et al (2000) Biodebridement: a case report of maggot therapy for limb salvage after fourth-degree burns. *J Burn Care Rehabil* 21(3):254–7
- Pritchard DI, Nigam Y (2013) Maximising the secondary beneficial effects of larval debridement therapy. *J Wound Care* 22(11): 610–6
- Telford G, Brown AP, Seabra RA et al (2010) Degradation of eschar from venous leg ulcers using a recombinant chymotrypsin from *Lucilia sericata*. *Br J Dermatol* 163(3): 523–31
- Thornton D, Berry M, Ralston M (2002) Case report: maggot therapy in an acute burn. *World Wide Wounds*. Available at: www.worldwidewounds.com/2002/august/Thornton/Larval-Therapy-Acute-Burn

